

Chamerhöck

März 2016

Jedi Ritter im Chirurgen-Alltag:

Laseranwendung für eine bessere
Atmung beim brachyzephalen
Syndrom

Dr Andreoni AA

Dipl European College of Veterinary Surgery ECVS

Brachyzephalen Rassen

Mops

Französische Bulldogge

Englische Bulldogge

Shih Tzu

Pekinese

Boston Terrier

Boxer



Wer ist Darth Vader und wer der Mops?



Beide atmen gleich

Woher stammt der Begriff
'Mopsfidel' oder Topfit



'Kindchenschema'

Wie erkennen wir ein BZS Patient

Stridor, Stertor und Schnarchen

Reverse sneezing

Wenig Belastbarkeit und kurze Ausdauer

Sehr empfindlich auf Wärme/Feuchtigkeit

Abdominale Atmung

Kopfbewegung beim Atmen

Synkopen

GI Probleme



Brachyzephalie Syndrom BZS

Primäres Problem

Enge Nasenlöcher

Langer Gaumensegel

Sekundäre Probleme

Eversion Larynxtaschen

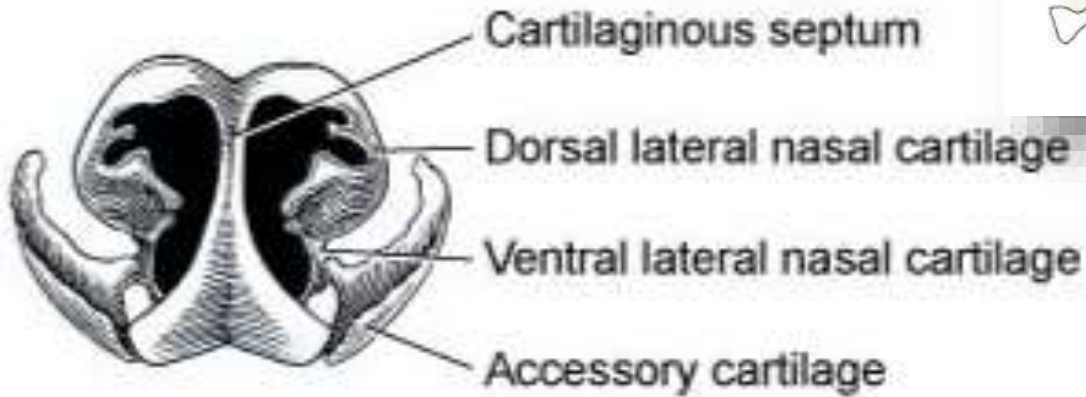
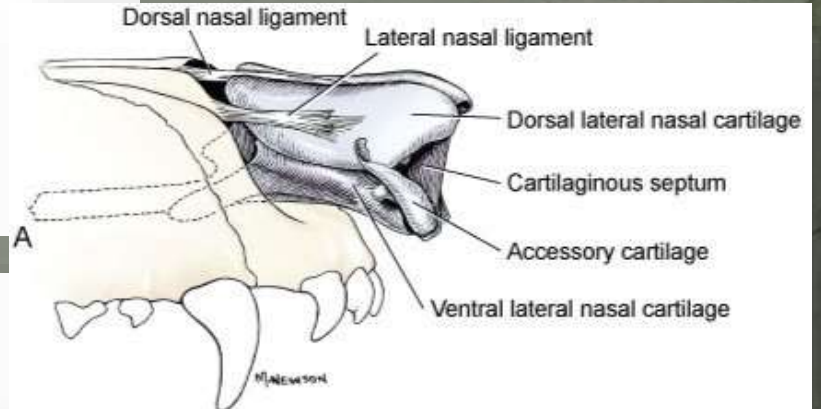
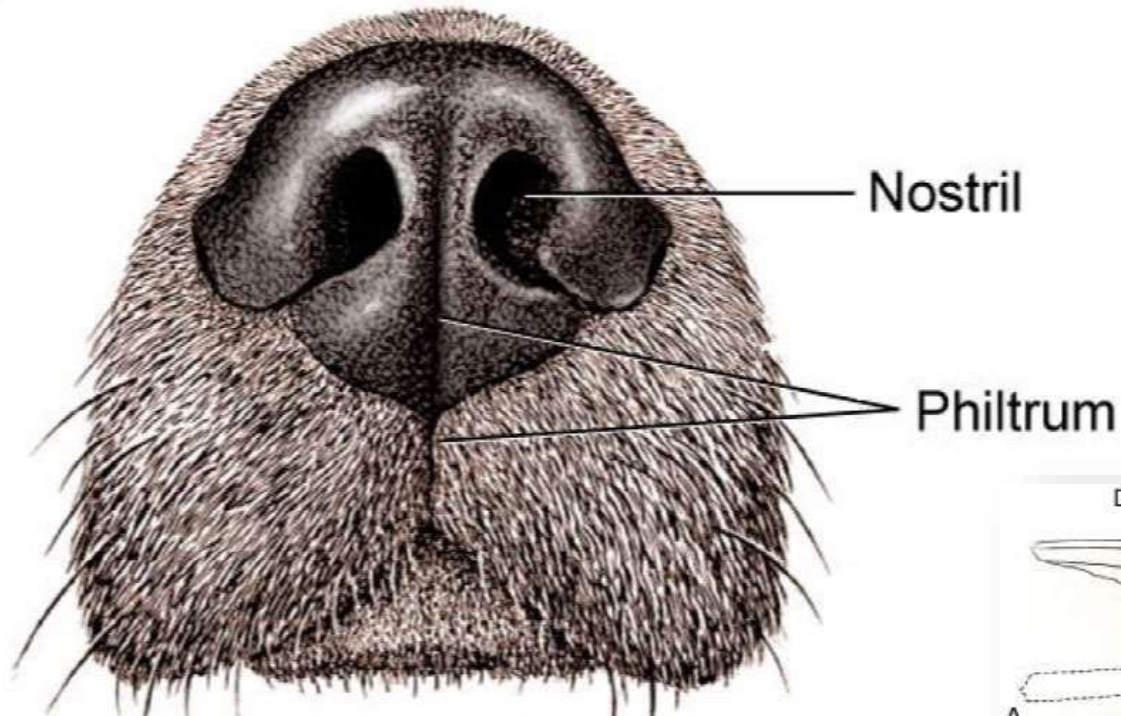
Kehlkopfkollaps

Bronchial/Tracheal

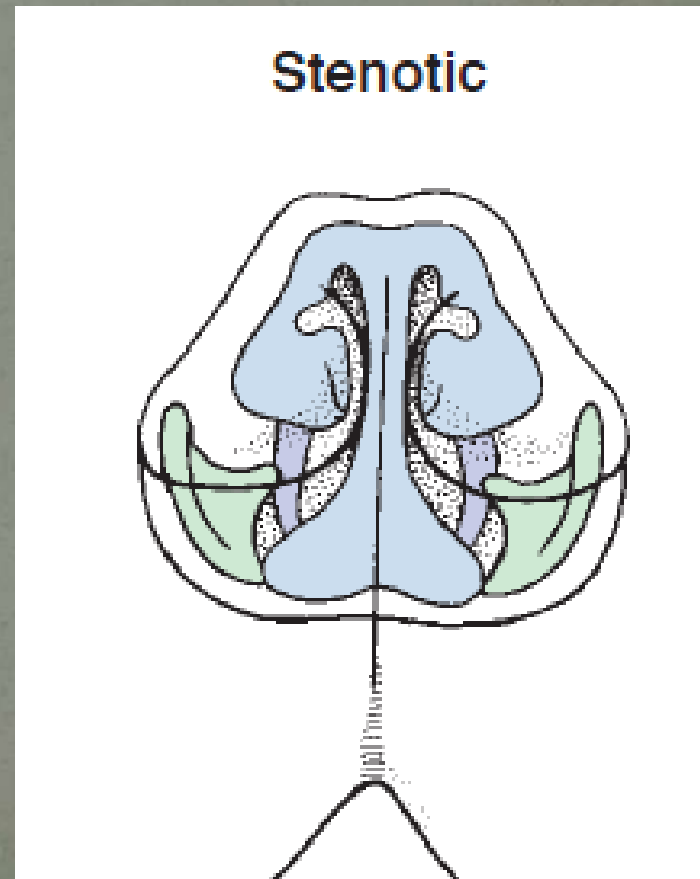
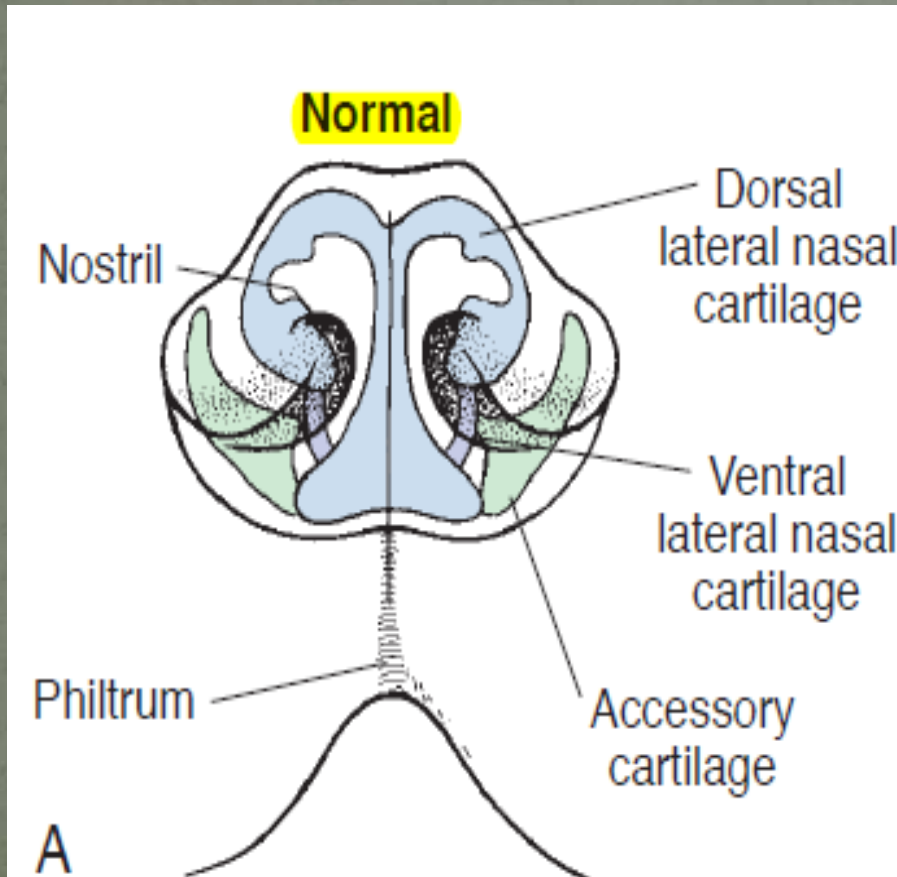
Kollapse

Hypoplastische Trachea

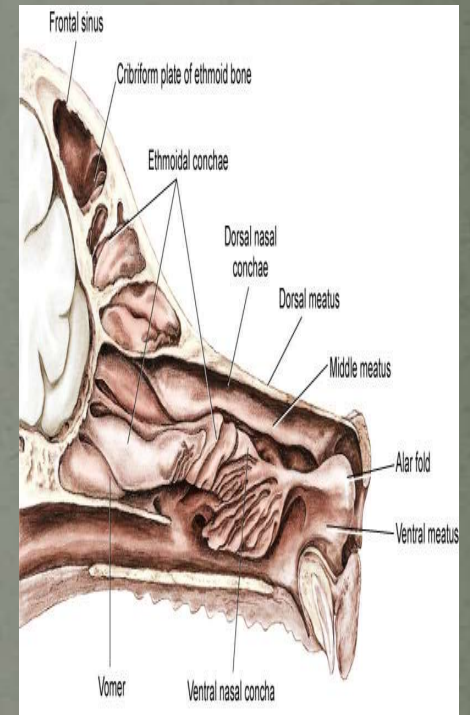
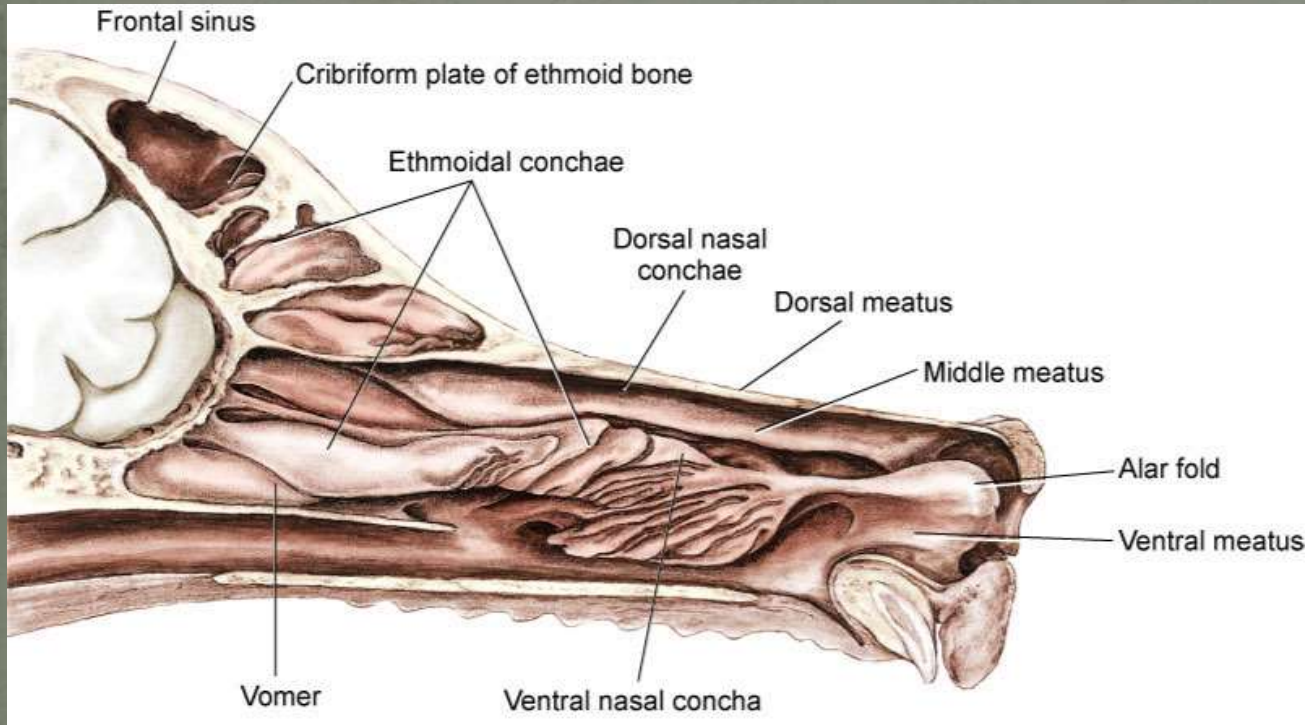
GI Probleme

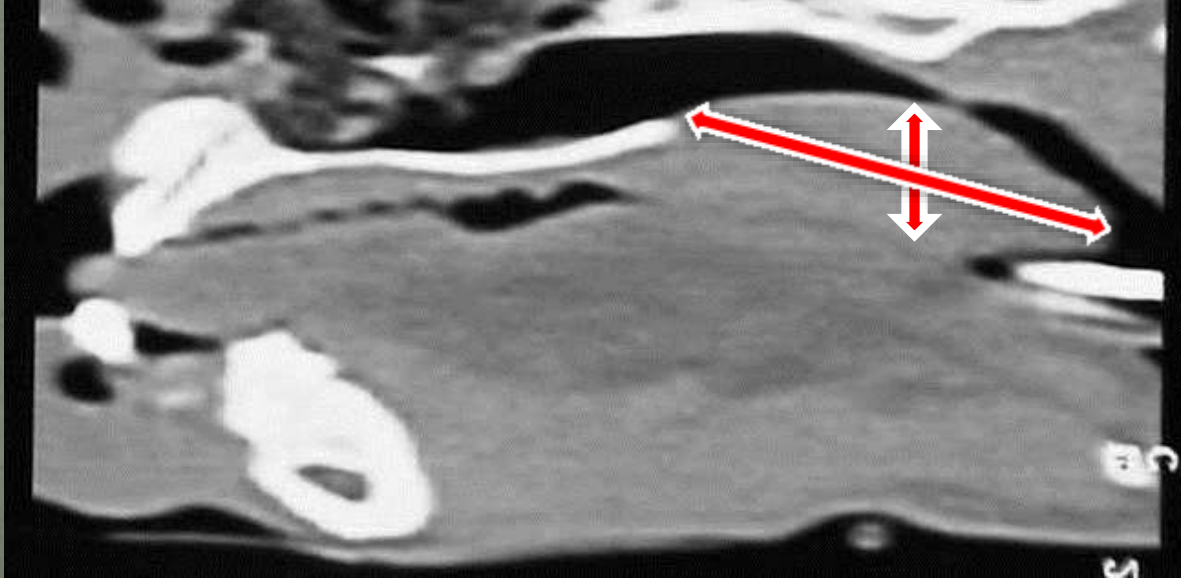
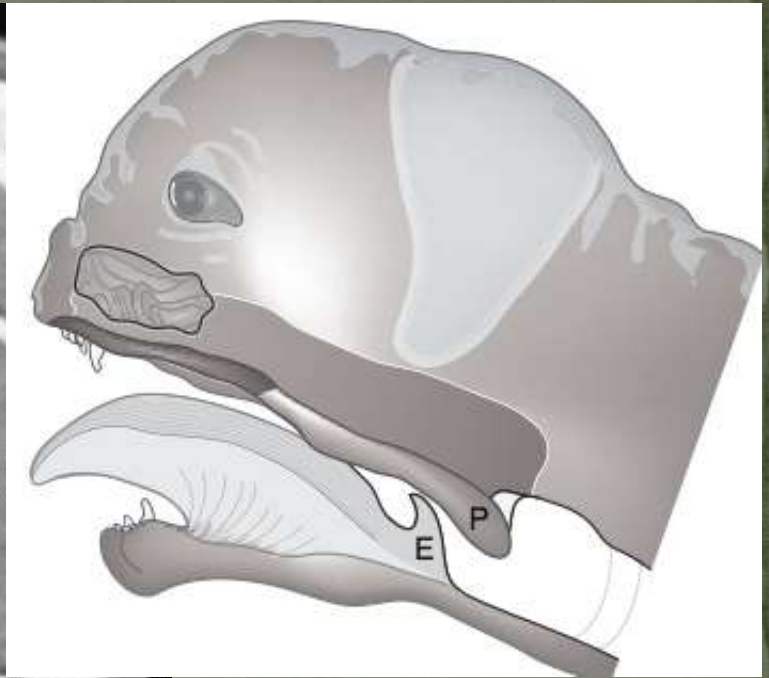
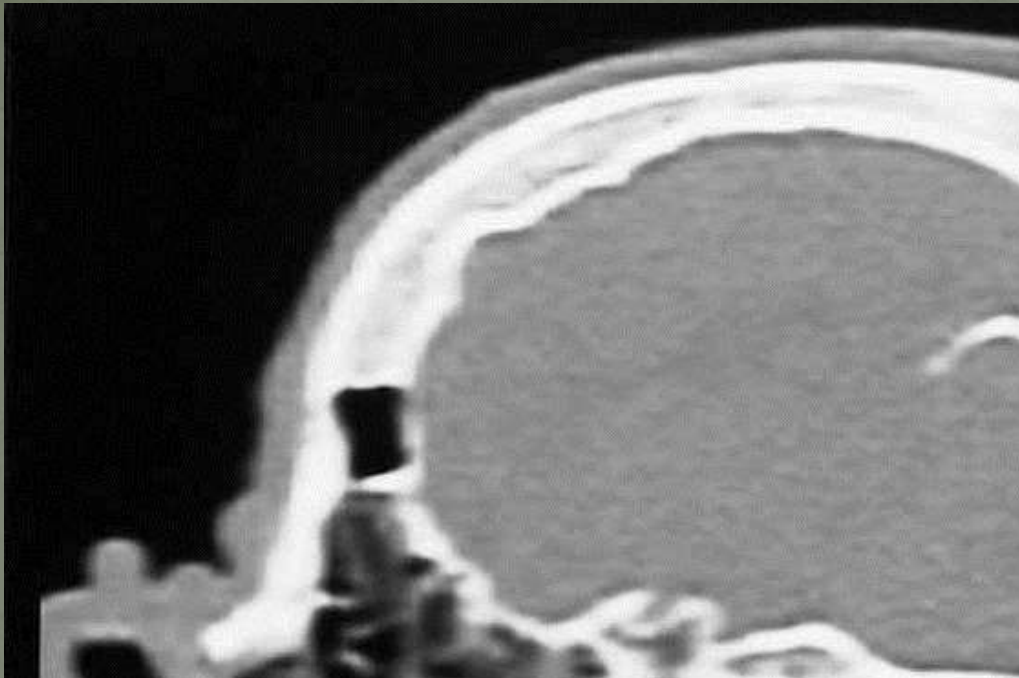


Normal vs Stenotisch



Dolicozephal vs Brachycephal





Wie können wir helfen?

Operieren und Tchüss

Nasenloch Plastik-Methoden

Vertikaler Kyle

Horizontale Kyle

Alar wing amputation -Trader's Methode

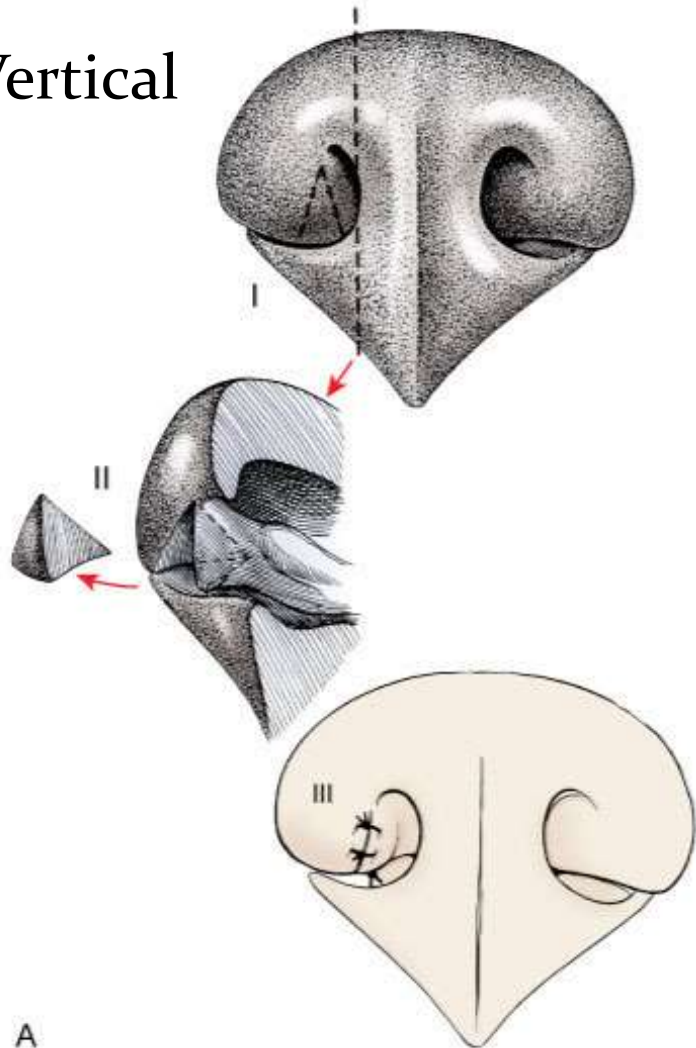
Punch Resektion

Modifizierte laser-assistierte Trader's Methode

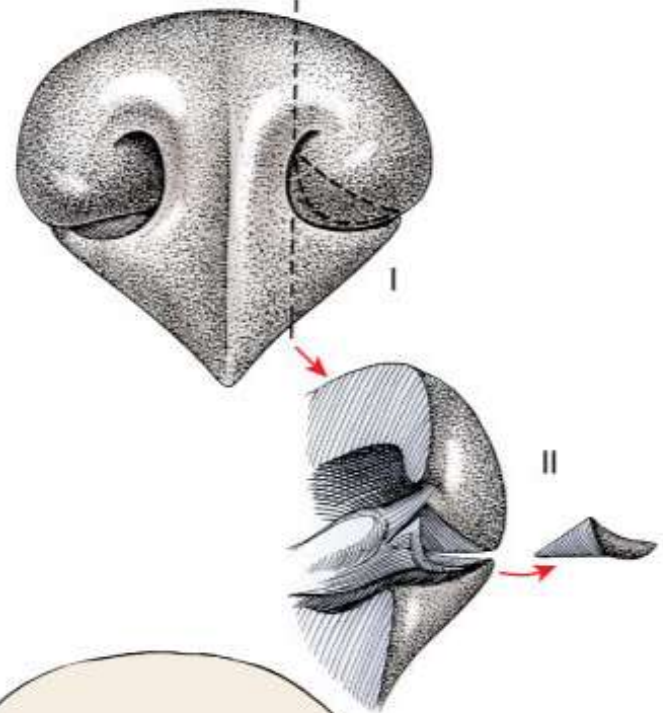
A-K oder 'Jediritter' Methode

Nasenlochplastik

Vertical



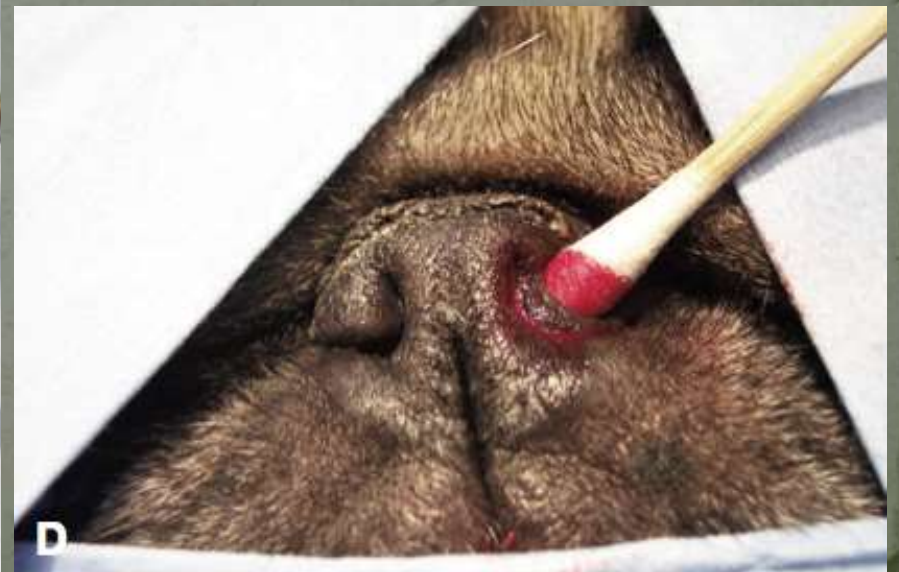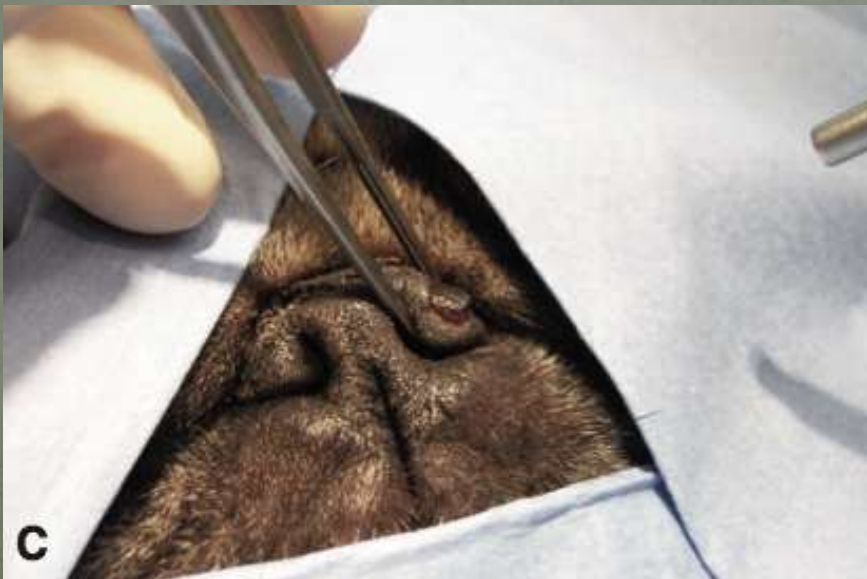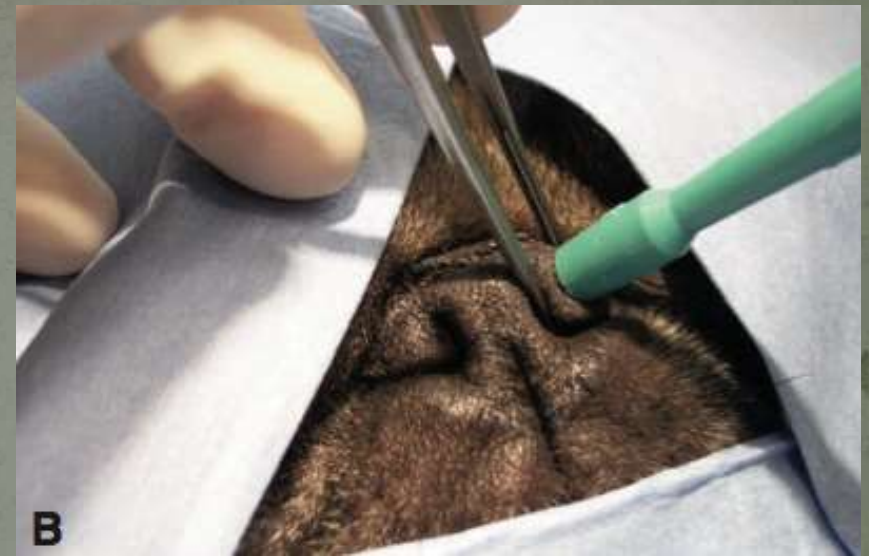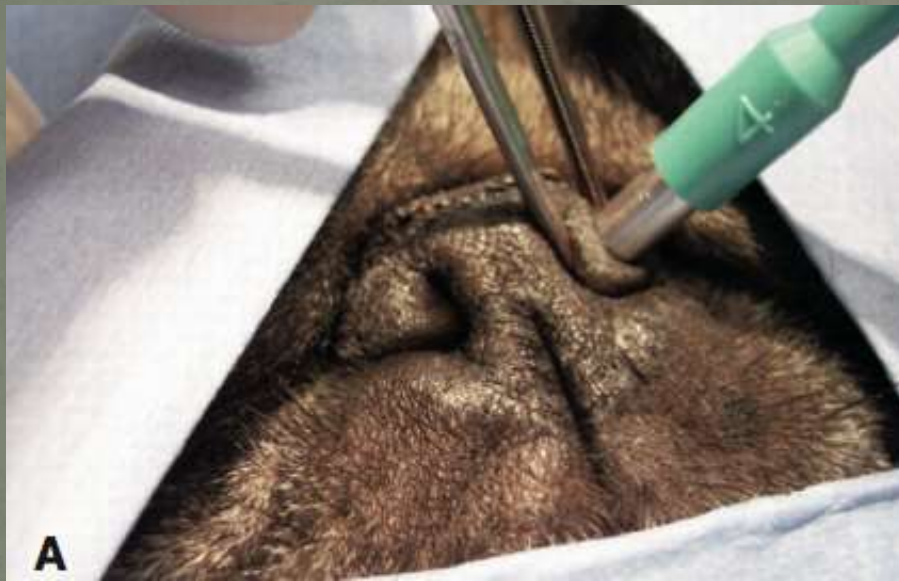A

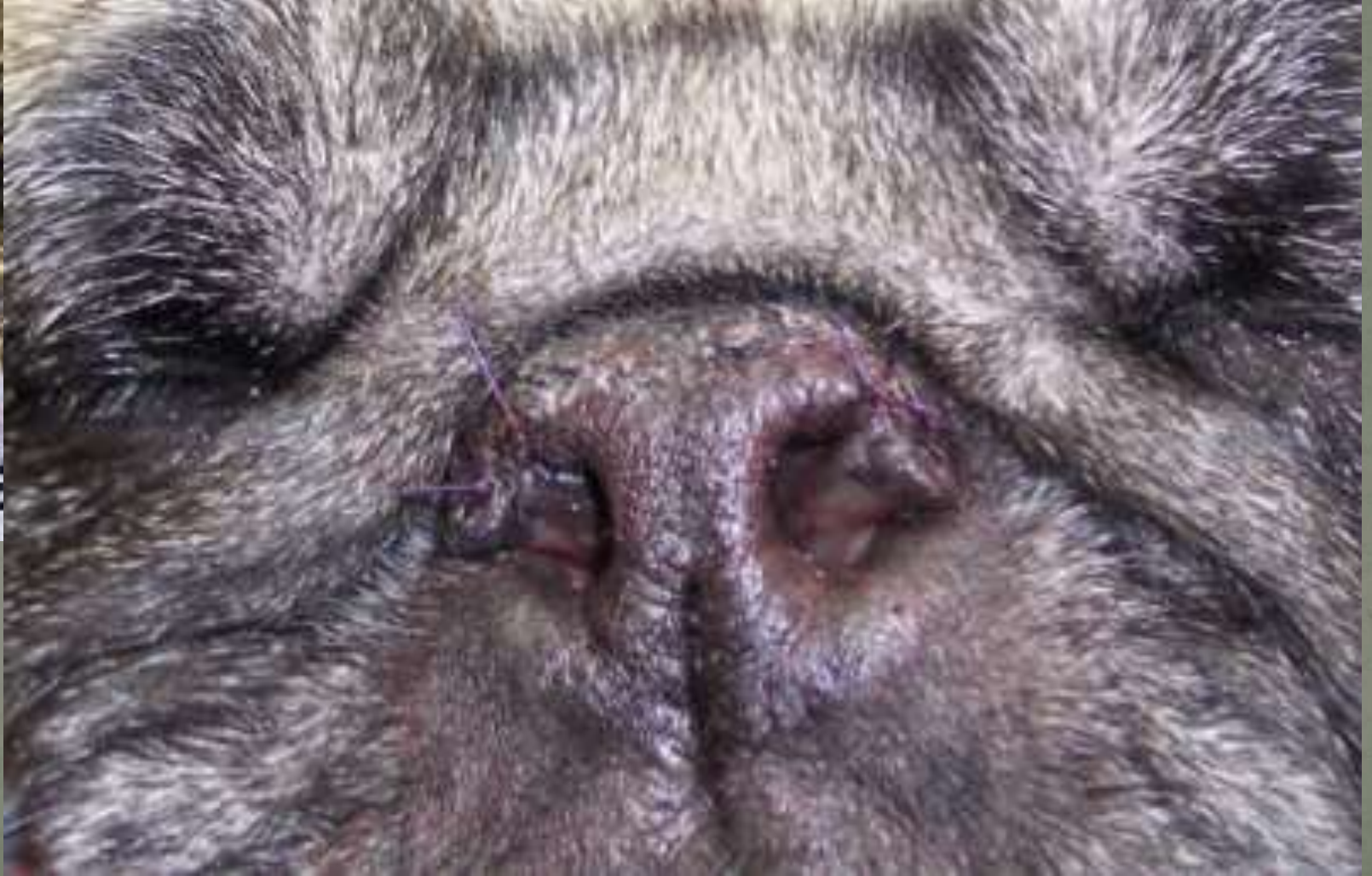


B

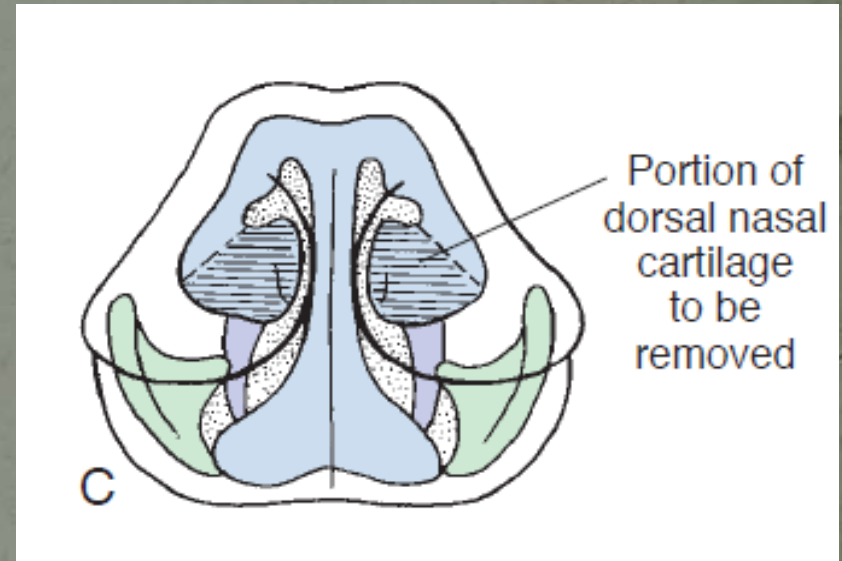
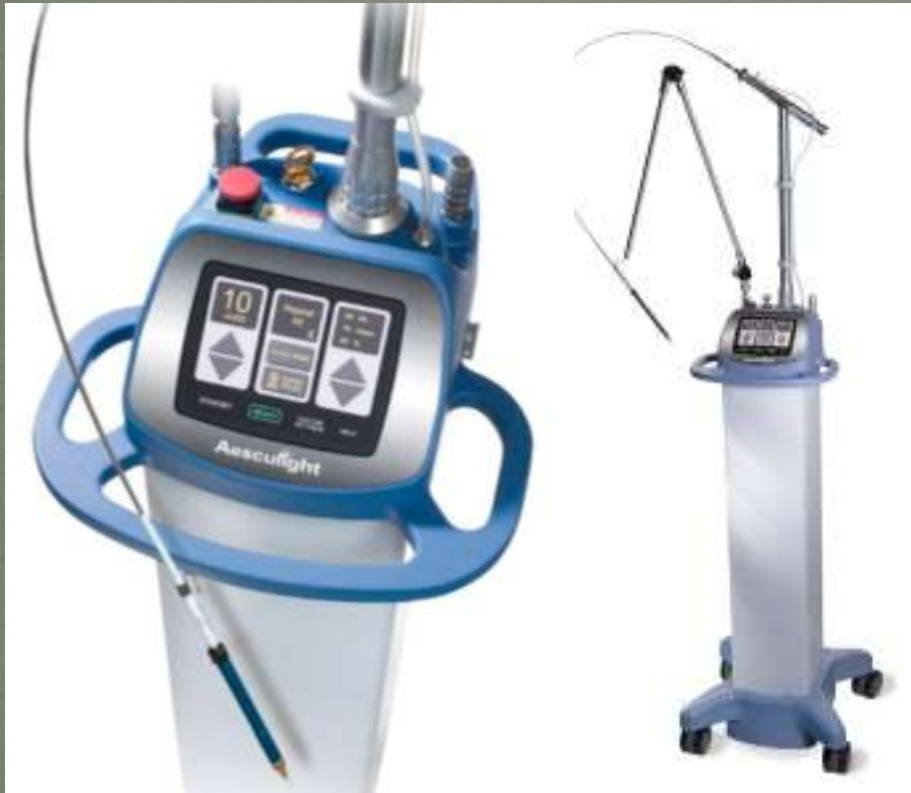Horizontal

Punch Alaplastie



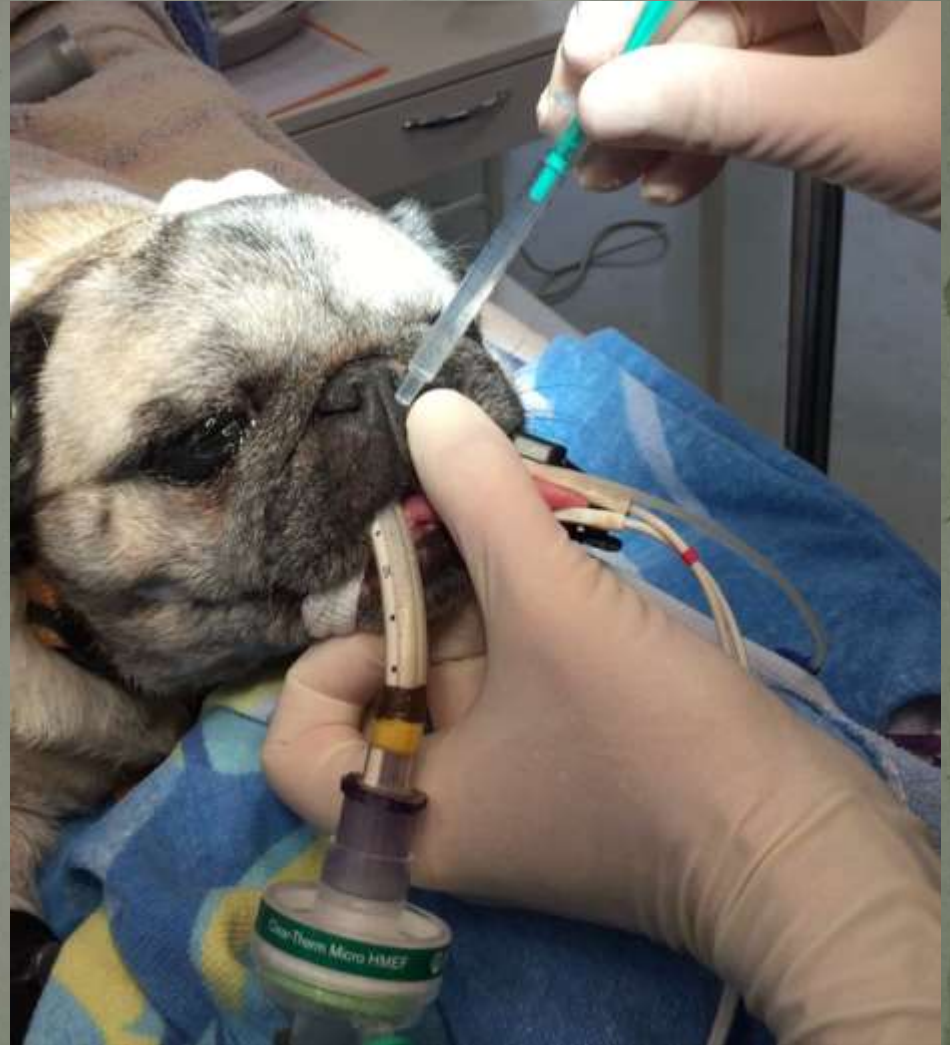

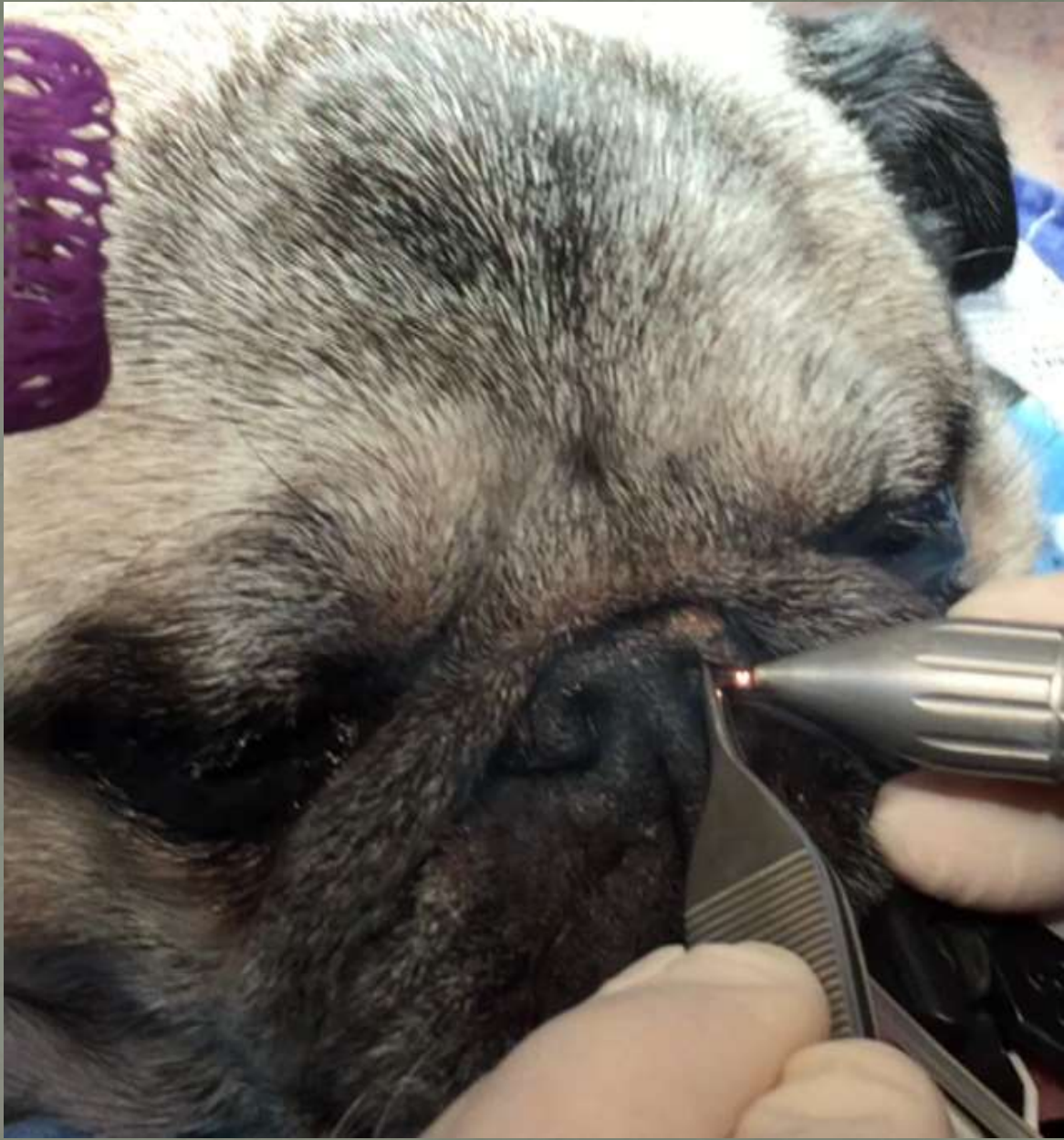
Laser assistierte Nasenflügel Amputation

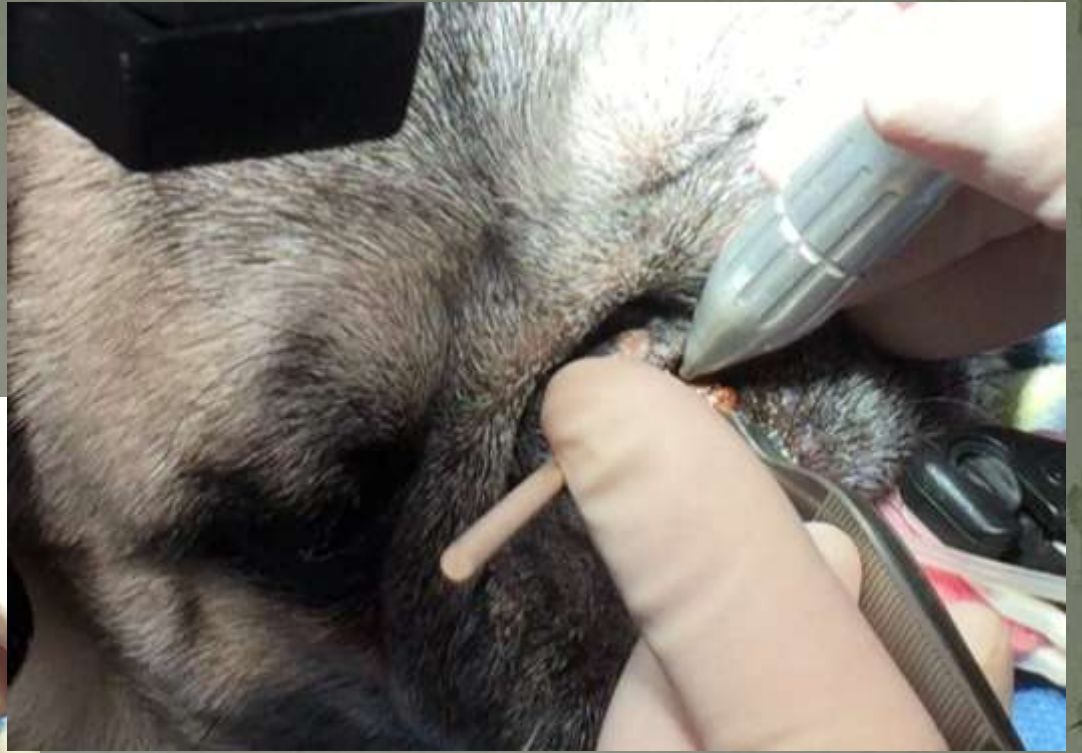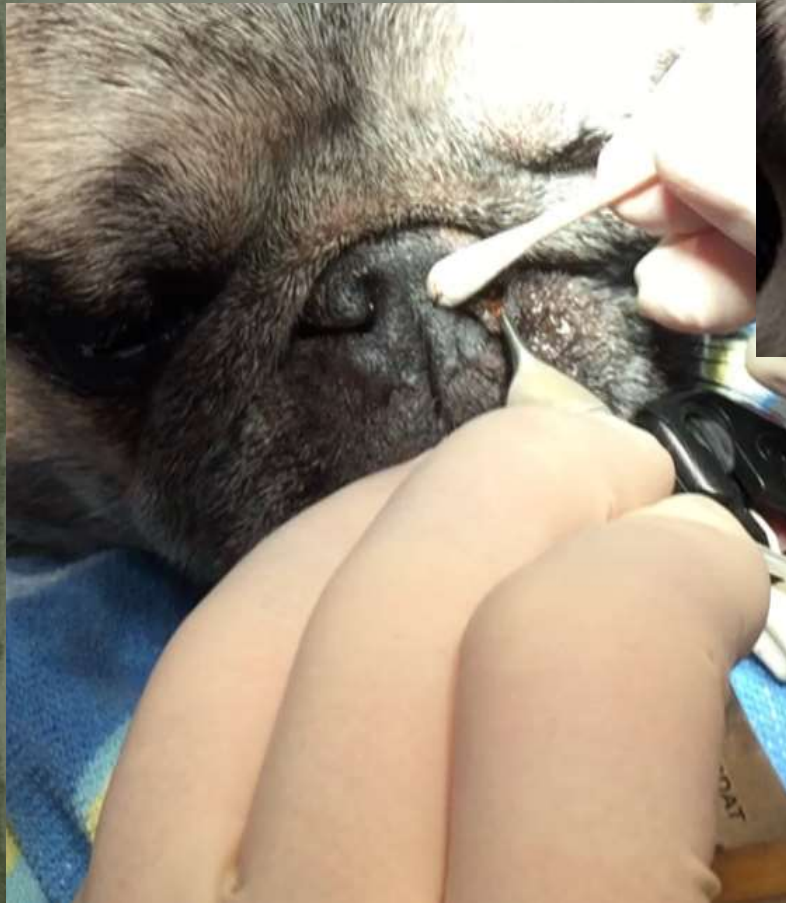


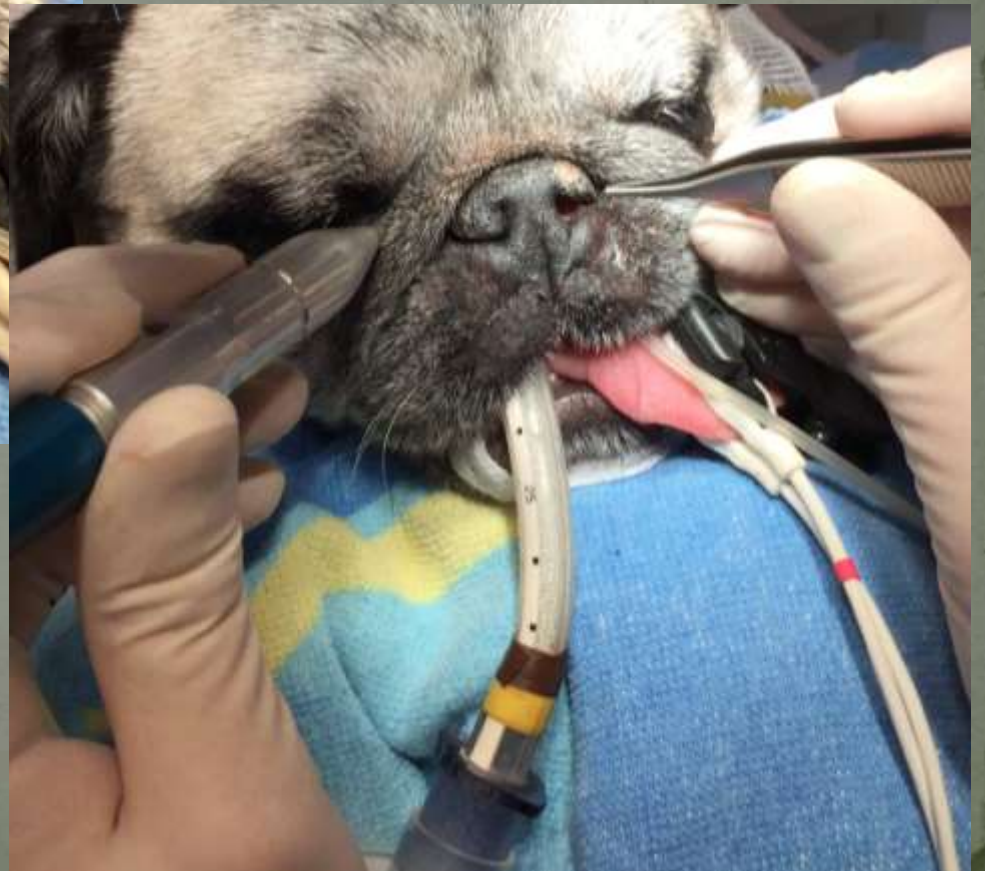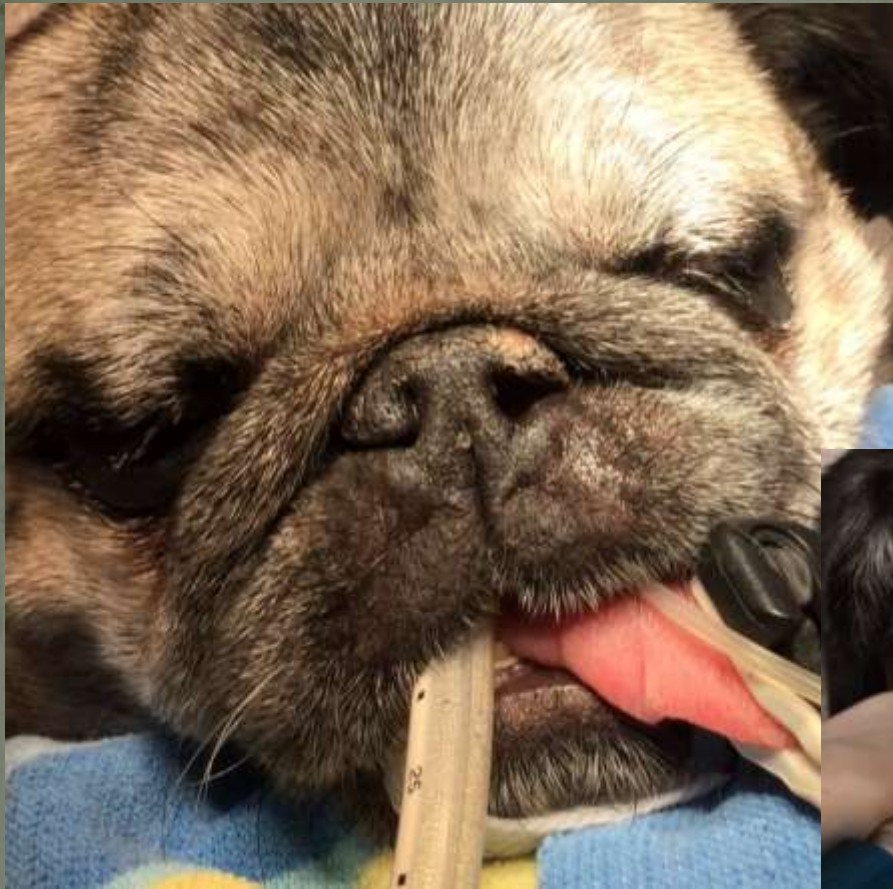CO₂ Laser

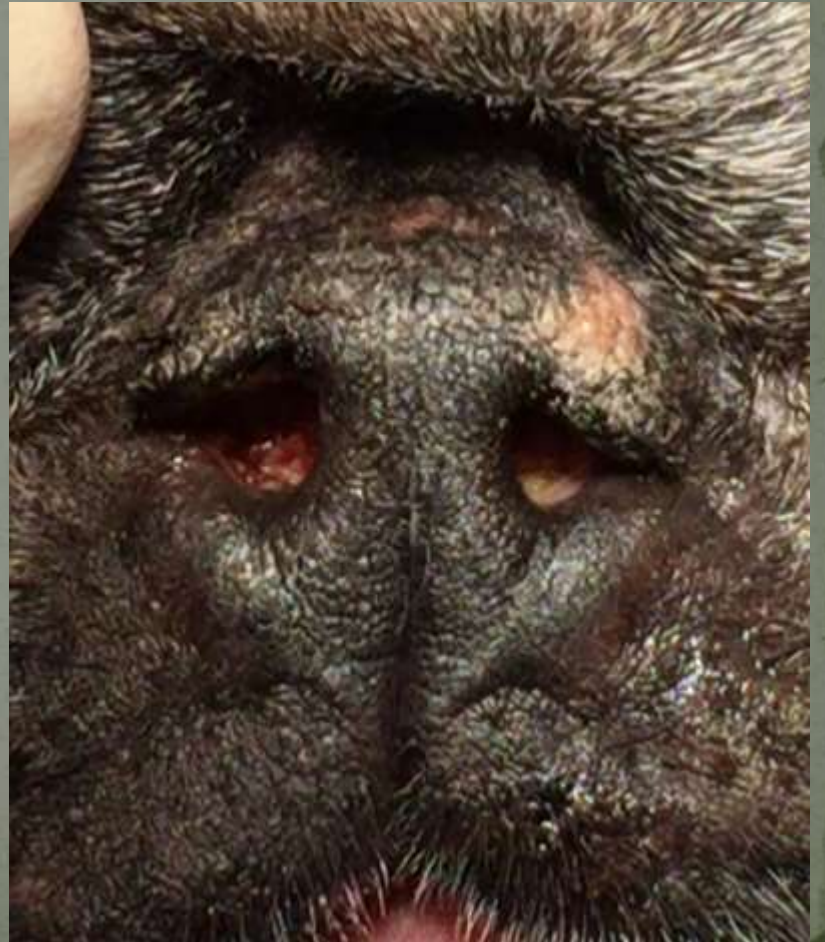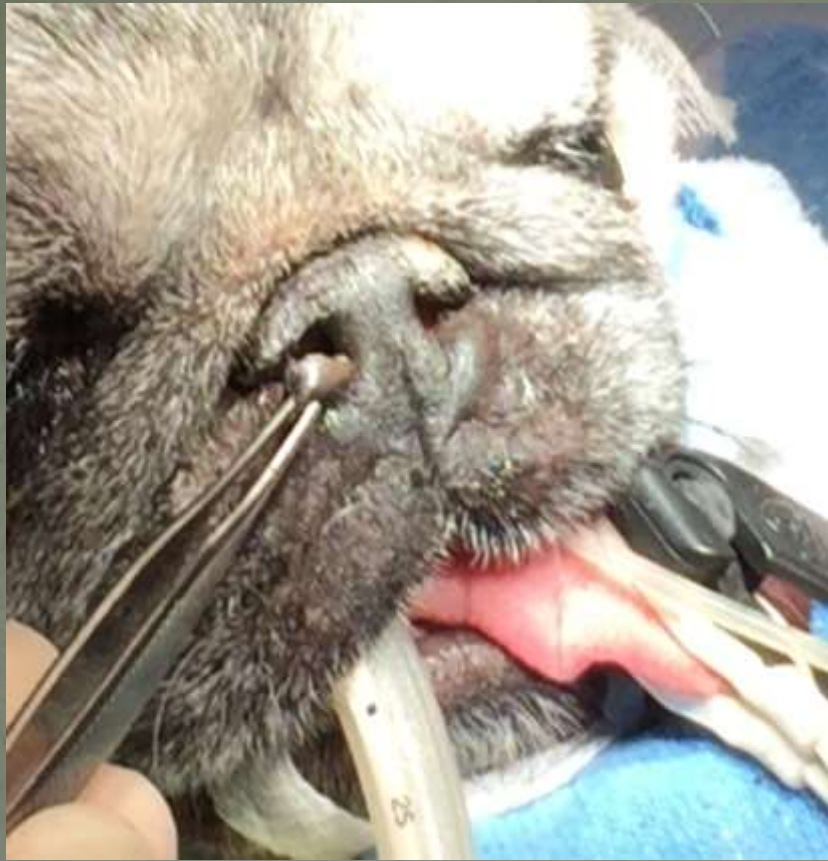
Lagerung und Lokalanästhesie für Nasenloch Plastik





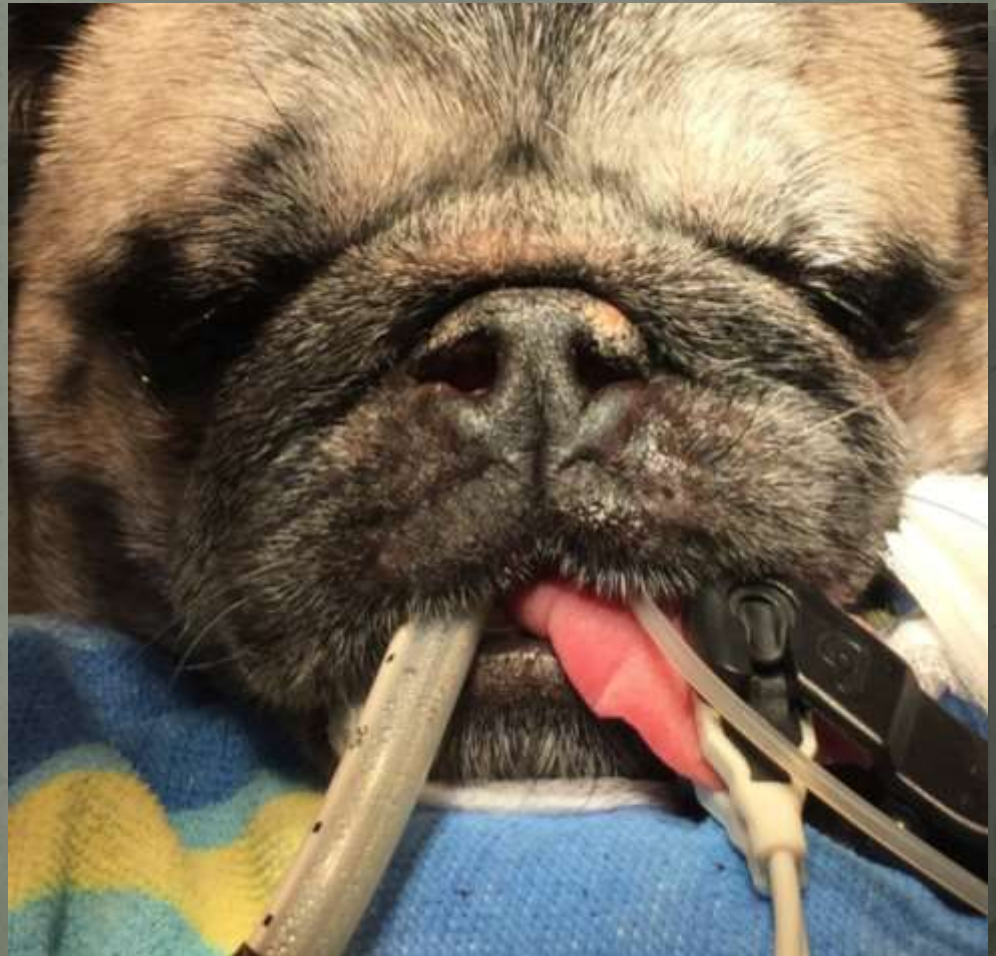


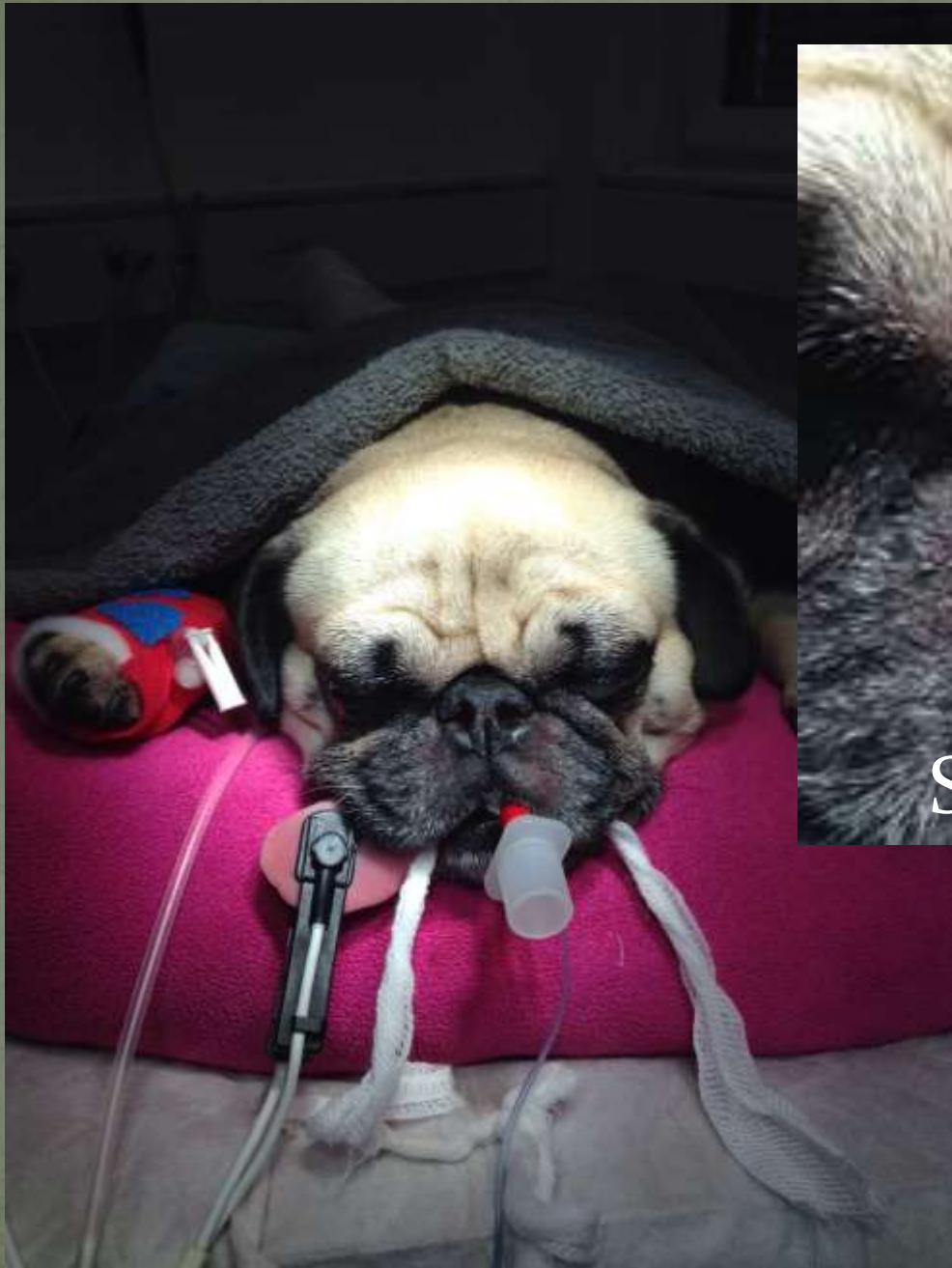



Und was ist besser daran?

Keine Blutungen
Bessere Übersicht
Schneller
Keine Fäden





Steckdosennäsli



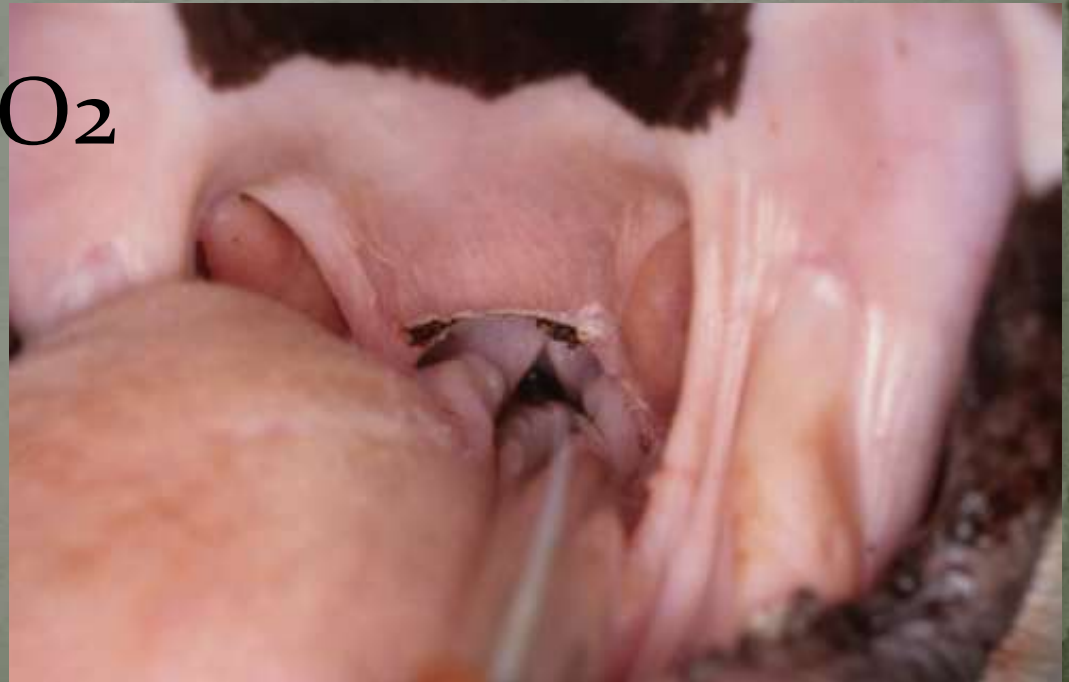Staphilektomie - Gaumensegelresektion

Standard Cut & Suture

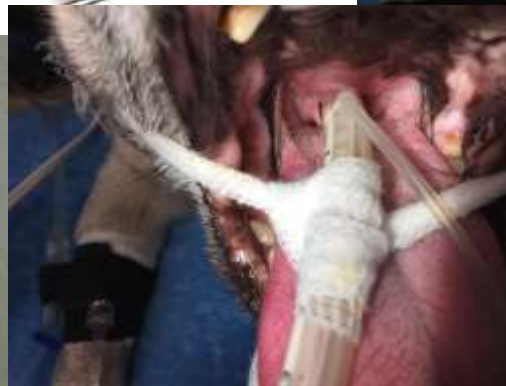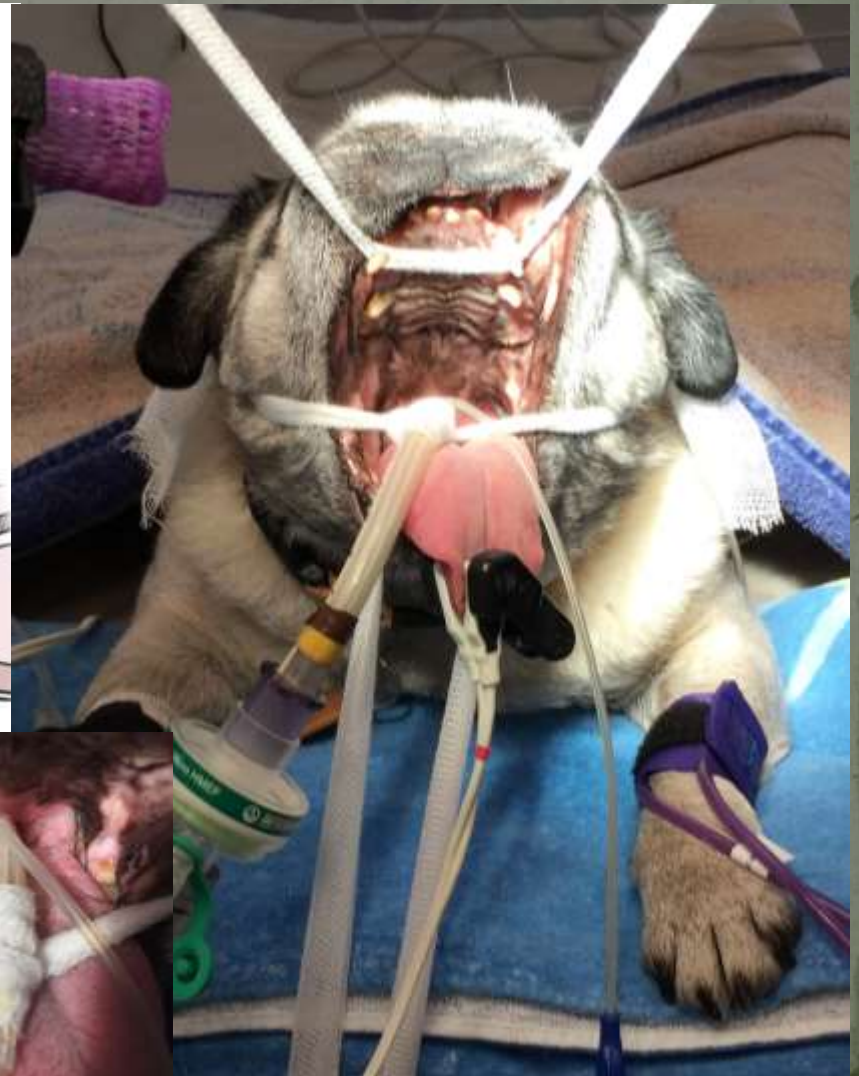
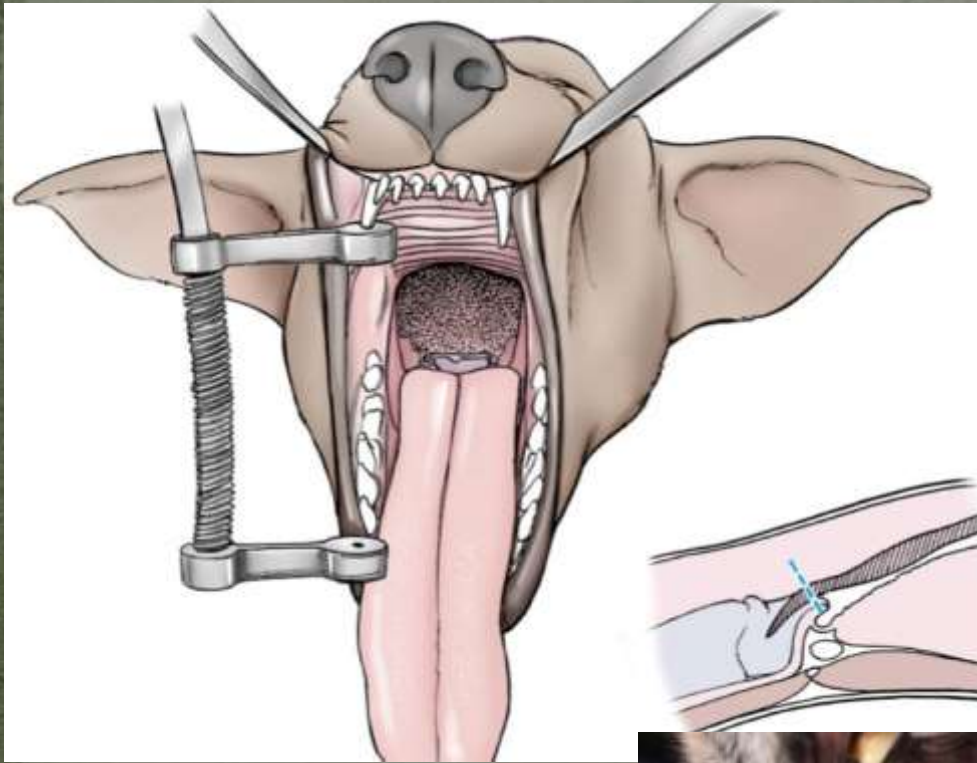
Ligasure assistiert

Staphiloplastie nach Duprè

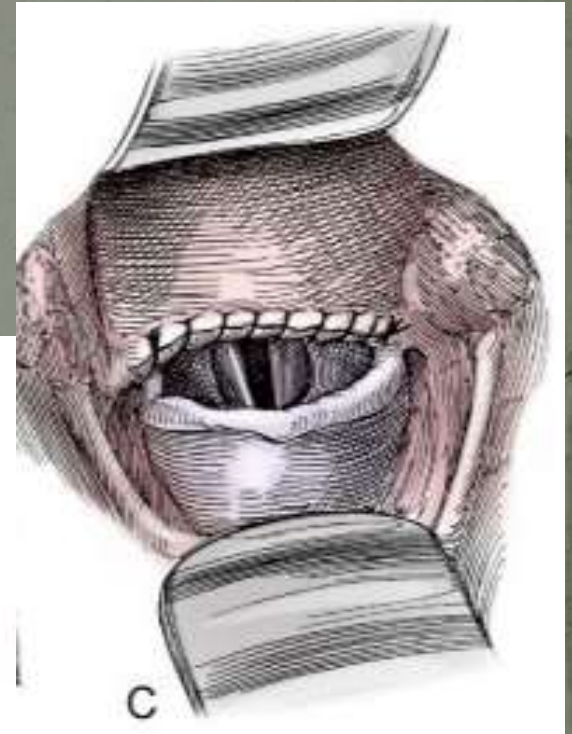
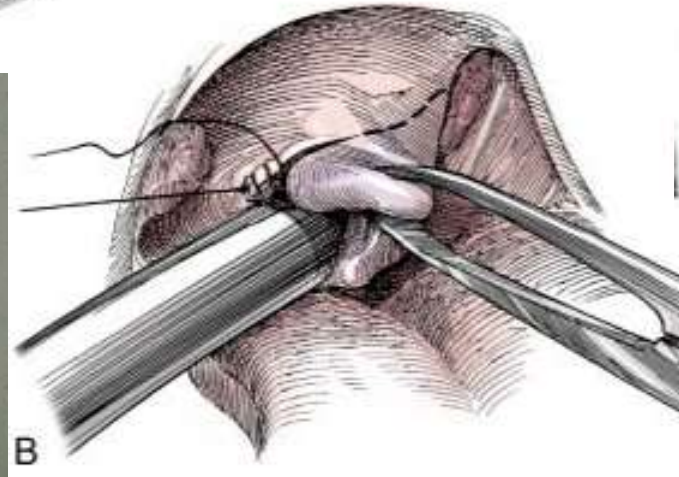
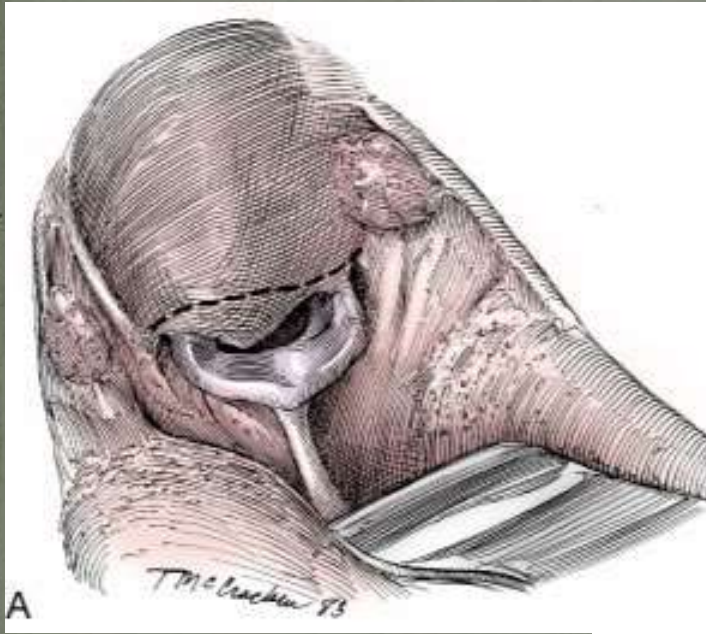
Laser assistiert CO₂

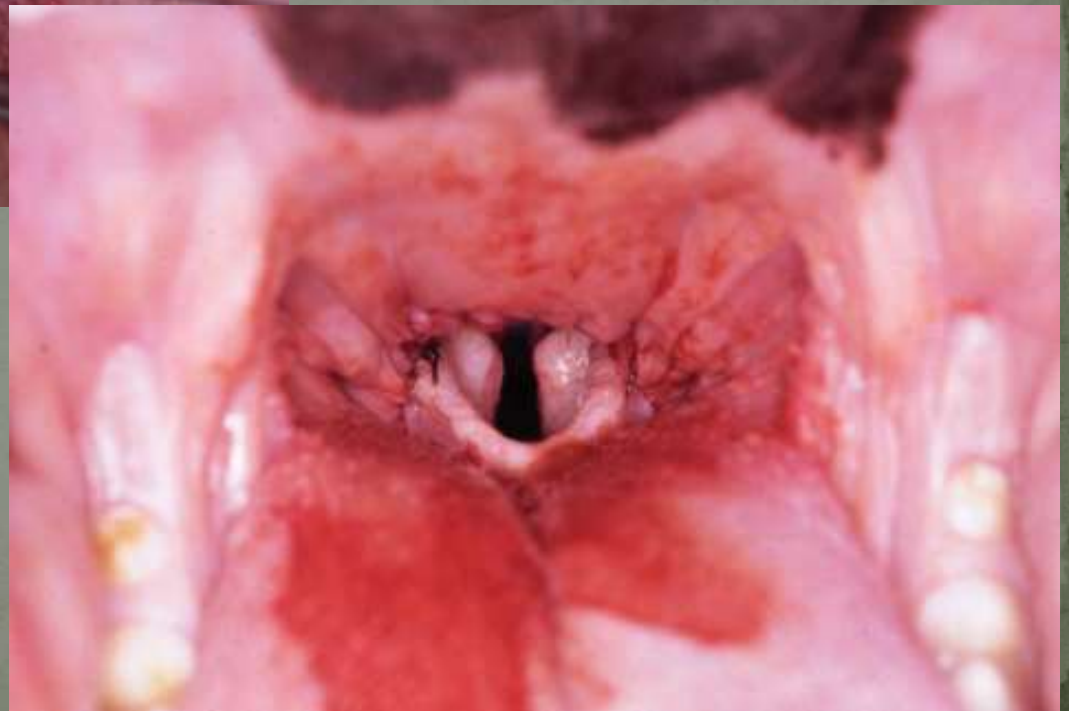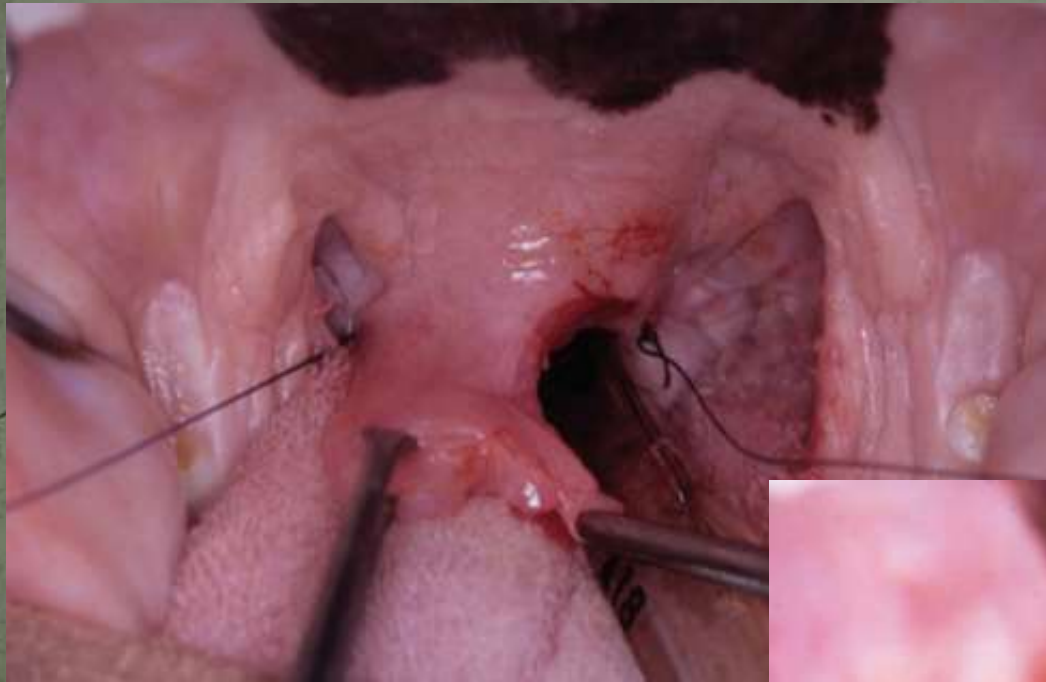


Lagerung für Gaumensegelresektion



Gaumensegelresektion Cut & Suture Methode

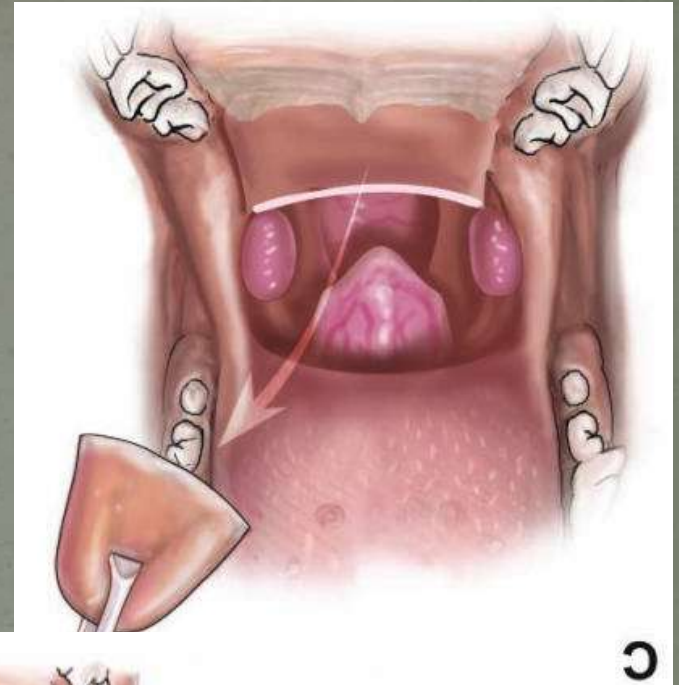
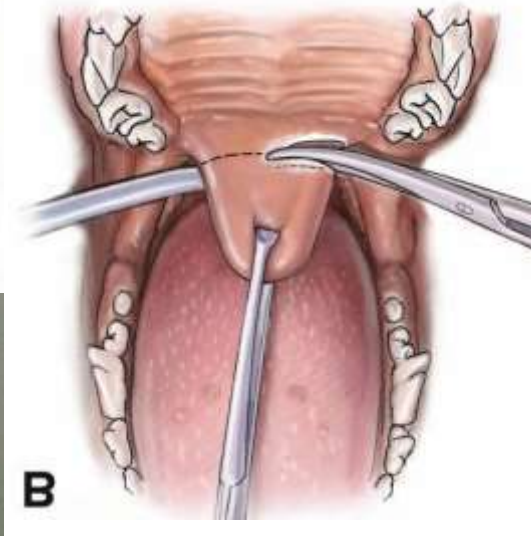
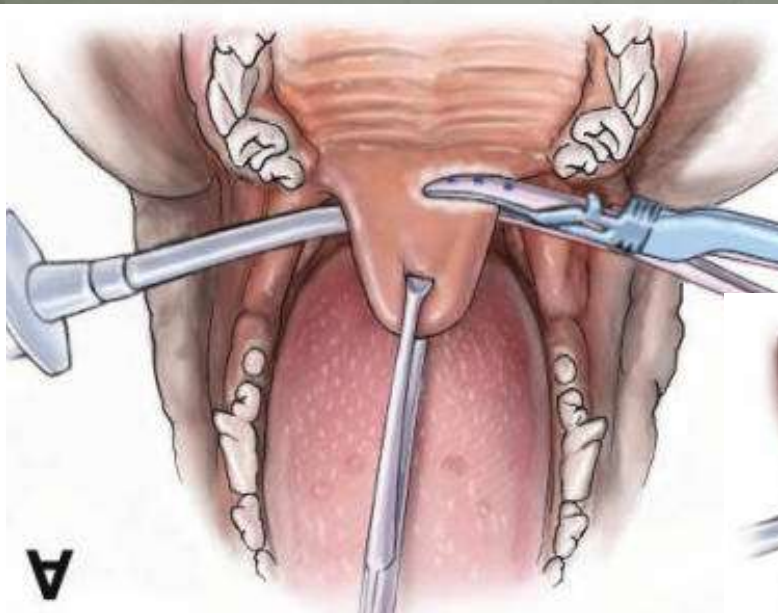




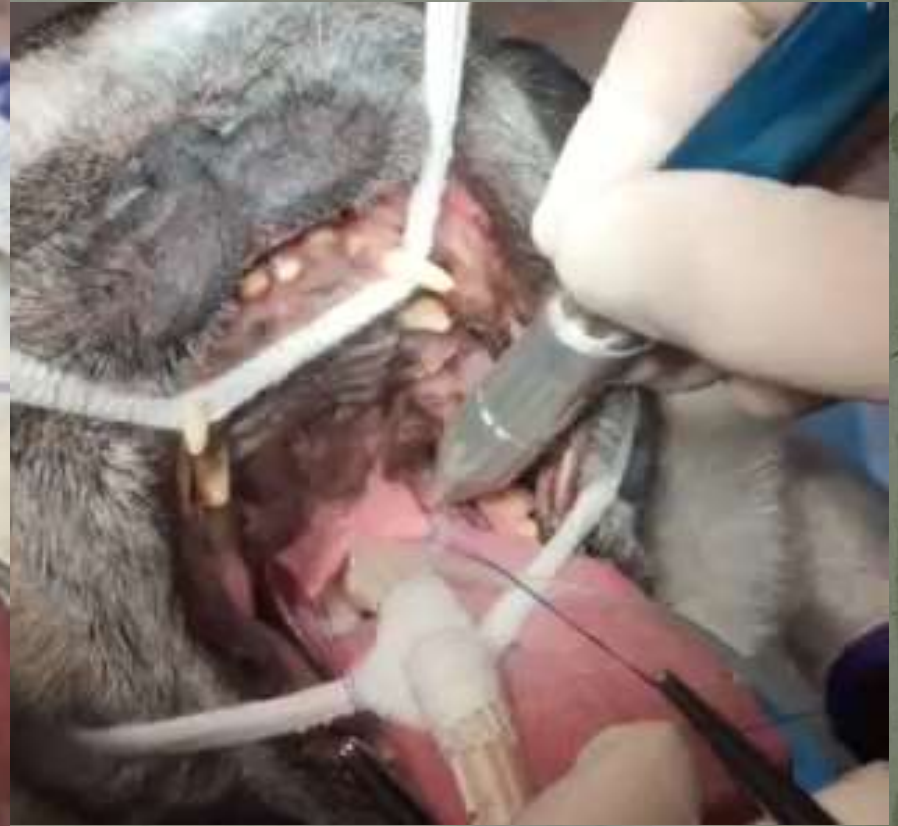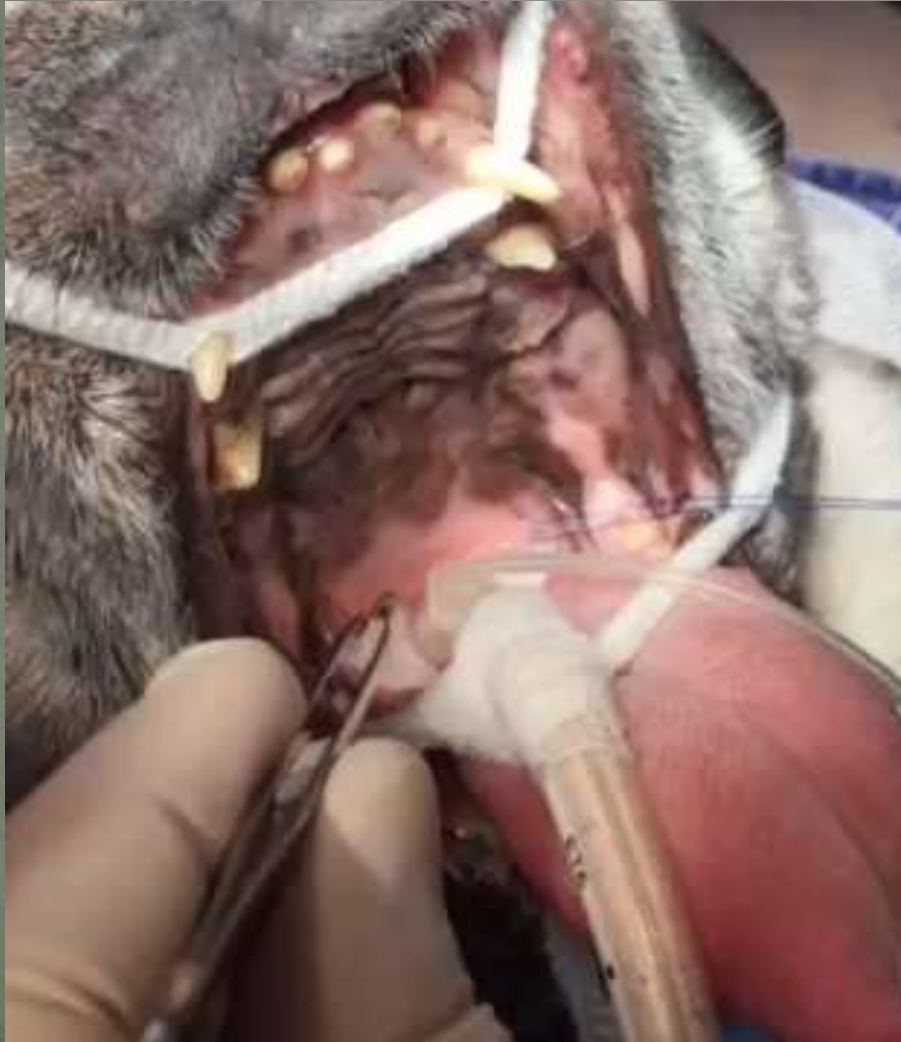Ligasure Staphylektomie

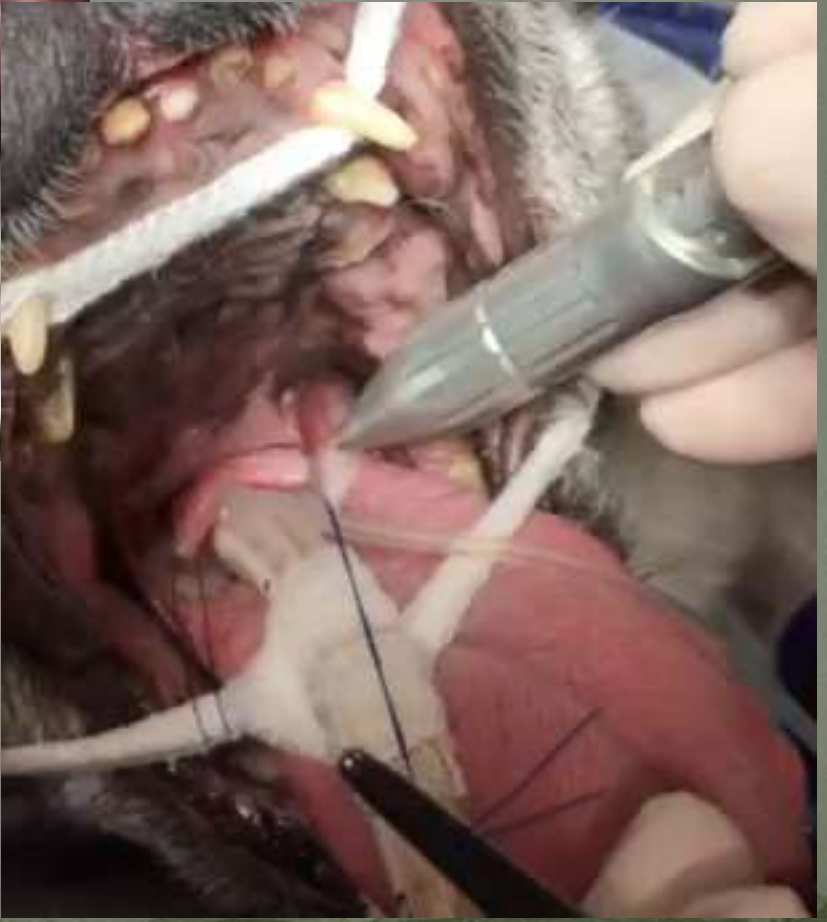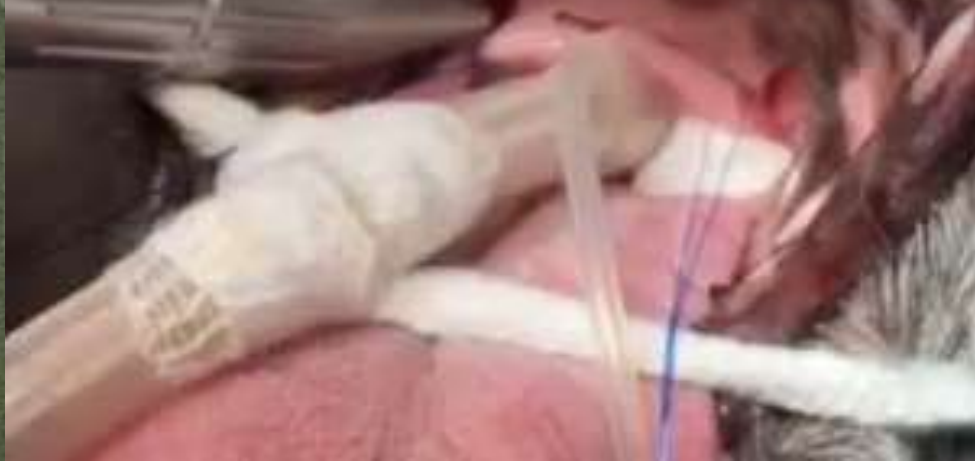Use of an electrothermal, feedback-controlled, bipolar sealing device for resection of the elongated portion of the soft palate in dogs with obstructive upper airway disease

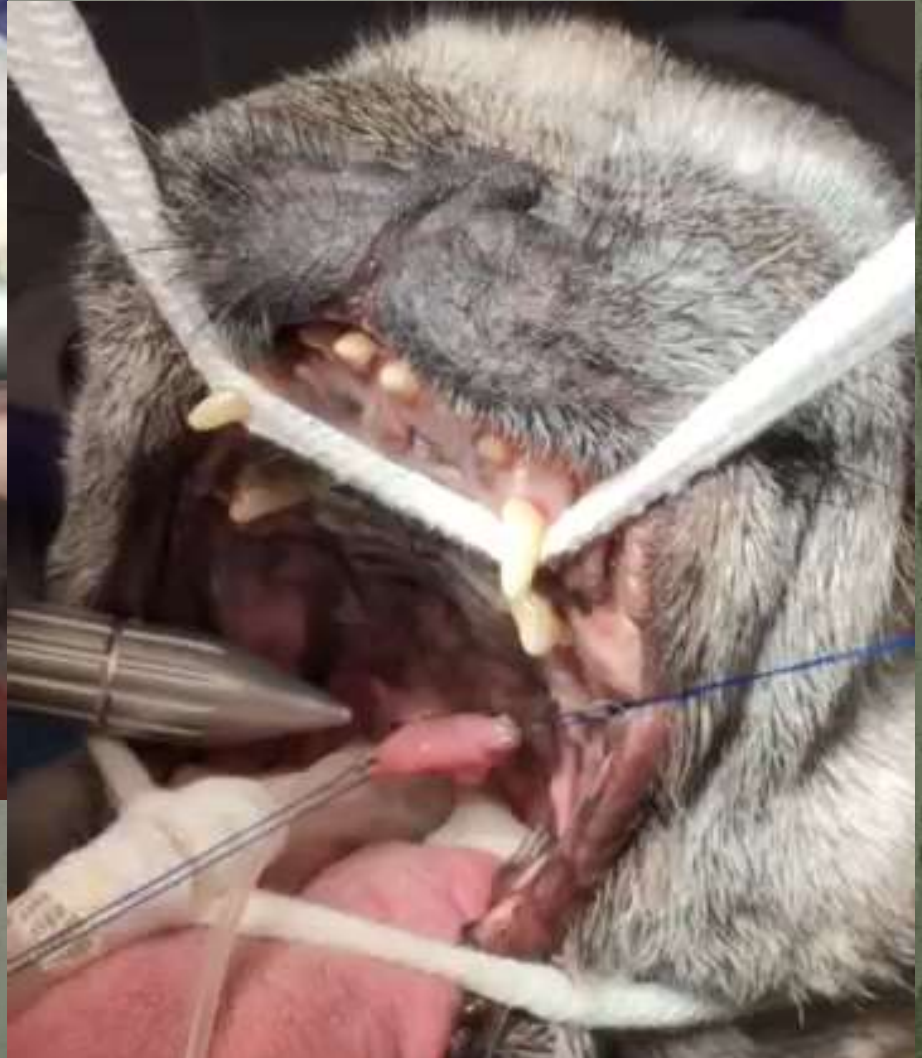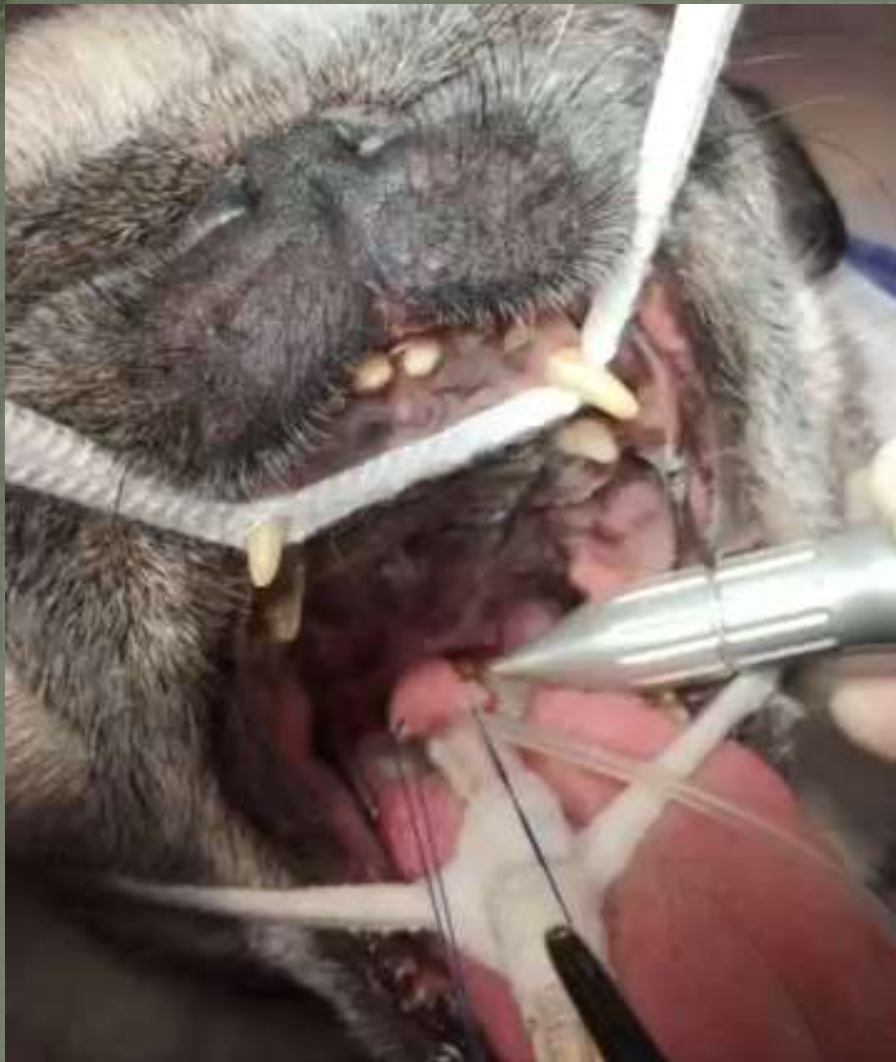David J. Brdecka, DVM, DACVS; Clarence A. Rawlings, DVM, PhD, DACVS;
Amanda C. Perry, DVM; Jonathon R. Anderson, DVM



Laser assistierte Staphilektomie







Und? Was ist so gut daran?

Es blutet nicht

Schneller

Weniger Gewebe Manipulation

Kein Fadenmaterial

Geringeres Anschwellen

Einfacher zum korregieren

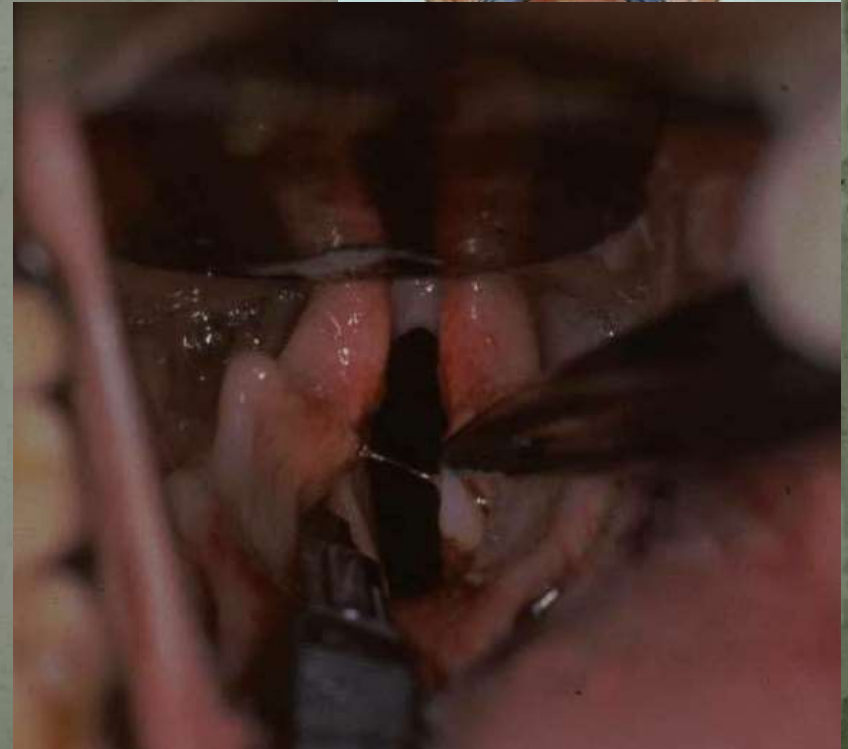
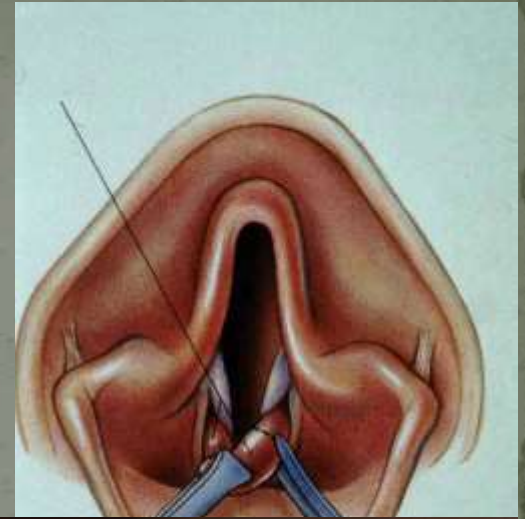
Nicht nur kürzer aber auch filetiert (dünner)

Sakkulektomie

Standard

Mit Ligasure

Laser assistiert CO₂



Und Tonsillektomie?

Keine Ahnung

Laser Assistierte Turbinektomie LATE

Prof. Oechtering
Leipziger Methode
Dioden Laser

Turbinektomie
Ventralen Nasenmuschel
Aberrante rostrale und
caudale Nasenmuschel



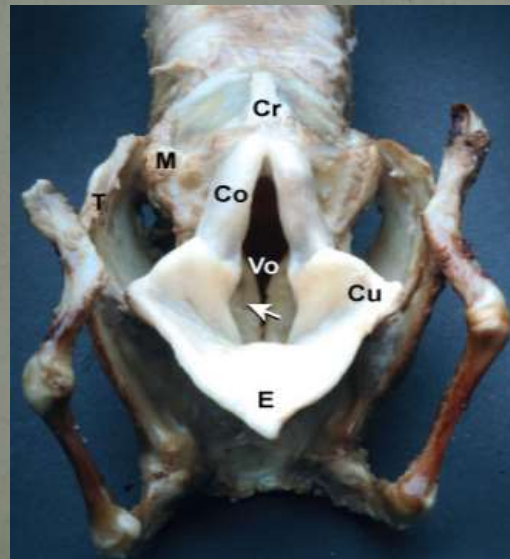
Results of surgical correction of abnormalities associated with brachycephalic airway obstruction syndrome in dogs in Australia

C. V. TORREZ AND G. B. HUNT*

University Veterinary Centre, Sydney, Faculty of Veterinary Science, University of Sydney, NSW 2006, Australia

Journal of Small Animal Practice (2006) 47, 150-154

Kehlkopf Kollaps Grad 1-3



OBJECTIVES: To describe clinical features of brachycephalic airway obstructive disease in dogs, the incidence of laryngeal collapse in dogs presenting for surgery and the outcome after surgery in dogs with laryngeal collapse.

METHODS: Basic clinical details were reviewed retrospectively in 73 dogs. Presence of laryngeal collapse and short-term outcomes after surgery were determined for 64 dogs with complete medical records. Long-term outcomes were reviewed for 46 dogs by telephone survey between 19 and 77 months following surgery.

RESULTS: Stenotic nares were present in 31 dogs (42.5 per cent), elongated soft palate in 63 (86.3 per cent) and everted laryngeal sacculles in 43 (58.9 per cent). The most common breeds were the pug (19 dogs, 26 per cent), Cavalier King Charles spaniel (15 dogs, 20.5 per cent), British bulldog (14 dogs, 19.2 per cent) and Staffordshire bull terrier (4 dogs, 5.5 per cent). Laryngeal collapse was present in 34 of 64 (53 per cent) dogs. No dogs died perioperatively and only one dog was euthanased as a result of its respiratory disease three years after surgery. Telephone interviews indicated that 26 dogs (56.5 per cent) were much improved after surgery, 15 (32.6 per cent) had some improvement and 5 (10.9 per cent) showed no improvement. Signs that persisted after surgery were snoring during sleep (34 dogs, 73.9 per cent), stertor/stridor while conscious (23 dogs, 50 per cent), excessive panting (13 dogs, 28.3 per cent) and dyspnoea (10 dogs, 21.7 per cent). Long-term outcome was considered good, even in dogs with laryngeal collapse.

CLINICAL SIGNIFICANCE: Laryngeal collapse is relatively common in dogs presented for surgical correction of brachycephalic airway obstructive disease. Dogs with severe laryngeal collapse often respond well to surgery. Clinical signs rarely resolve completely following surgery.

Und postoperativ?

Ein Schuss Dexa (0.1 ml/Kg)

Omeprazol 0.7-1 mg/Kg
einmal täglich

Metoclopramide 2-5mg/Kg Bi-Tid

Ranitidin 1-2 mg/Kg Bid

Eis oder kaltes jogurt ab sofort

Onsior 1-2 mg/Kg einmal täglich

48h postop für 5-7 Tagen



Prevalence of gastrointestinal tract lesions in 73 brachycephalic dogs with upper respiratory syndrome

Long-term results of upper respiratory syndrome surgery and gastrointestinal tract medical treatment in 51 brachycephalic dogs

C. M. PONCET, G. P. DUPRE,
V. G. FREICHE AND B. M. BOUVY

Gleichzeitige Behandlung der GI Probleme

Dysphgie und Erbrechen

Missbildungen: Hiatale Hernie
Pylorus Stenose
GE Reflux

Niedrigere Komplikationsrate

OBJECTIVES: After a first clinical study showing a high prevalence of gastrointestinal tract diseases in brachycephalic dogs presented for upper respiratory syndrome, a prospective study was performed to determine the influence of medical treatment for gastrointestinal tract disorders associated with upper respiratory syndrome surgery.

METHODS: The gastrointestinal tract and respiratory disorders of 61 brachycephalic dogs presented for upper respiratory syndrome were evaluated. Together with surgery of the upper respiratory tract, a specific gastrointestinal medical treatment was administered. A minimal follow-up of six months was required for inclusion.

RESULTS: Palatoplasty with rhinoplasty was the most common surgical correction (88.5 per cent). The mortality rate in the perioperative period was 3.3 per cent. Minor complications accounted for 26.2 per cent of cases. No aspiration pneumonia was encountered. A sufficient follow-up was obtained in 51 dogs. The improvement was judged by the owners as excellent or good in 88.3 per cent of the respiratory disorders and in 91.4 per cent of the gastrointestinal disorders. Clinically, a statistically significant improvement was obtained for both respiratory and gastrointestinal disorders.

CLINICAL SIGNIFICANCE: In comparison with other studies, digestive tract medical treatment combined with upper respiratory surgery seems to decrease the complication rate and improve the prognosis of dogs presented for upper respiratory syndrome.

LUZI



‘Making Assessments of Dogs Respiration’ Special breed specific instructions for judges – BSI

produced by the Swedish Kennel Club is excellent:

http://www.youtube.com/watch?v=kQ_3f4bLkME&feature=share